W. G. Penfield.
American Red Cross Hospital
6 Rue Piccini
Paris.

Peter Bent Brigham Hospital
Boston.

Apparatus of Dr. Blake

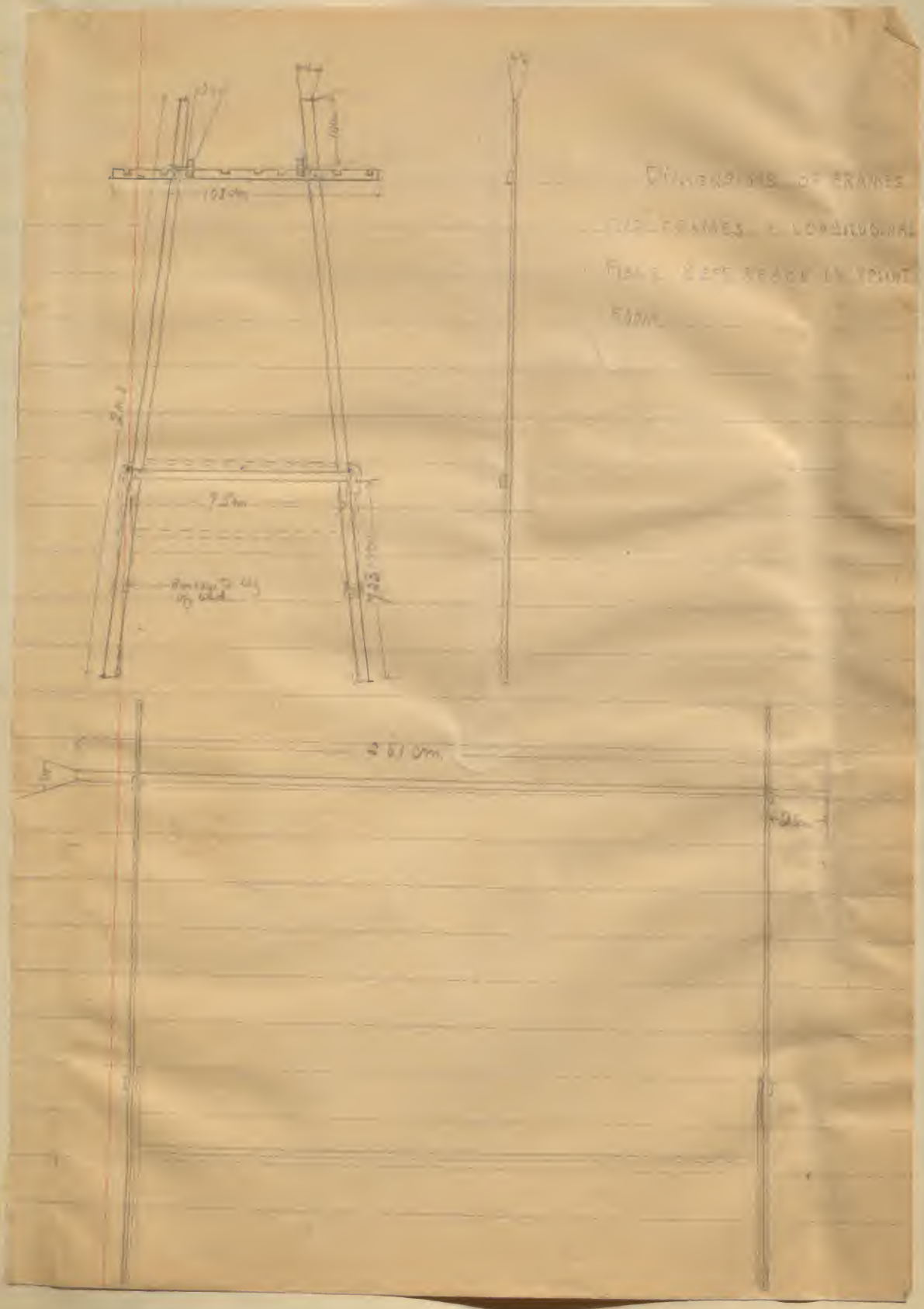

Sinclair Skate.

The strips of felt are sewed to small curtain rings. Each strip is cut as desired and glued to foot (Heussners glue gave good results) The two posterior strips are run a little way up tendo-achilles. Strips are bound on with bandage while drying.

The skate is well padded and attached several hours later. By adjusting the cross bar the leg should be kept in external rotation. By alteration of the attachment of the extension rope inversion of foot may be provided.

Raising and lowering the sling supports of the leg lowers or raises the toe ie decreases or increases the dorsiflexion.

As in other extensions of leg an average of 4 lbs. is used.

Sinclair Skate

4.

Heussner's Glue for Extension

(1) Formule:	Colophane	50.0
	Alcool à 90 0/0	50.0
	Térébenthine de Venise	1.0
	Benzine	10.0

} Patient must be shaved. Bandage on for ½ hour. Glue will then hold well. Soluble in alcohol + ether.

Inclaias glue.

	ms cc.
Common glue	200
Thymol	4
Calcium Chloride	4
Glycerine	8
H_2O	200.

} no need to shave patient. Dissolves in water. Must be heated each time before use. Do very messy.

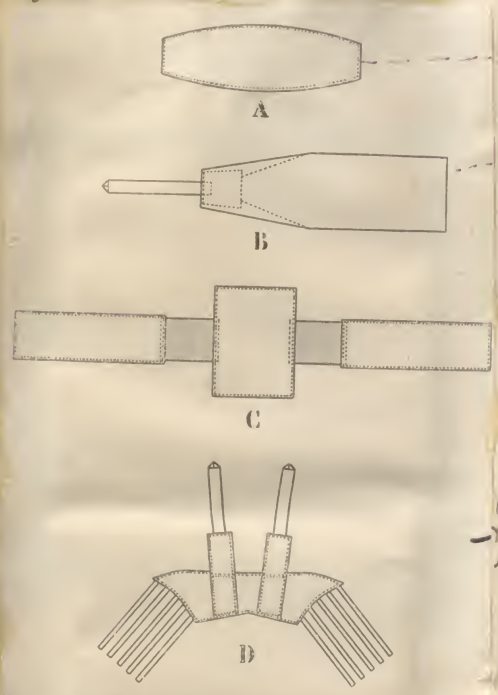

Fig. 2. — A) Bande pour supporter un membre lorsqu'il est fixé dans une attelle.
B) Bandes d'extension en finette à coller sur le membre.
C) Support pour empêcher la chute du pied: la partie centrale, plus large, est placée à la plante du pied; les parties ombrées sont en tissu élastique.
D) Guêtre pour l'extension lorsque les bandes adhésives ne peuvent pas être employées.

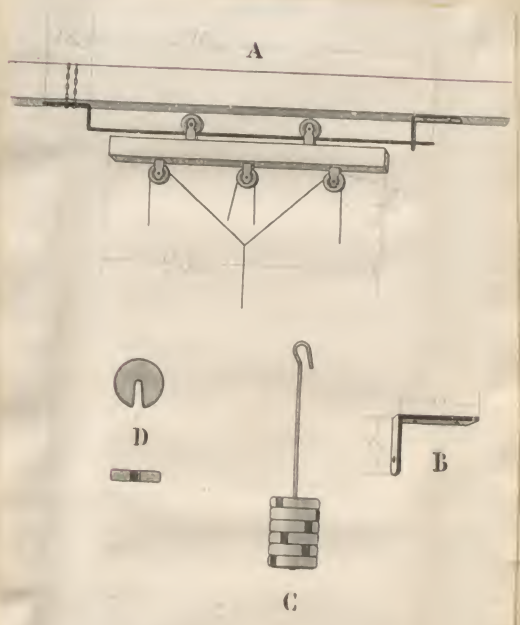

Fig. 1. — A) *Détails du trolley.* La barre en fer du trolley est recourbée à son extrémité gauche et fixée à la barre en bois située au-dessus; son extrémité droite, au contraire, passe dans un trou pratiqué dans l'équerre B), laquelle est elle-même fixée à la barre en bois du dessus. C) et D). *Détails du poids en plomb.*

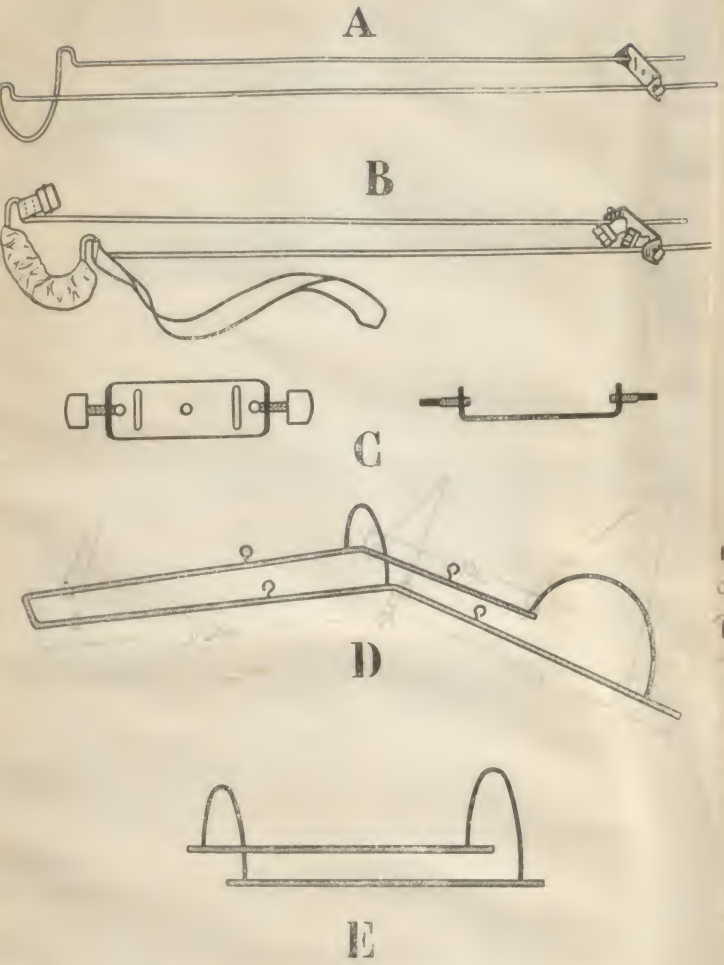

Blade Splint

Hooks on Hodgens are misplaced. Points of attachment for best results in suspending leg are shown.

Fig. 15. — A) Attelle modifiée de Thomas pour fracture du fémur.
B) La même attelle rembourrée, avec pièce transversale munie de boucles.
C) Détails de la pièce transversale.
D) Attelle de Hodgens.
E) Cadre en fer pour la suspension de l'avant-bras.

FRACTURE OF HUMERUS

SUSPENSION, EXTENSION, ABDUCTION

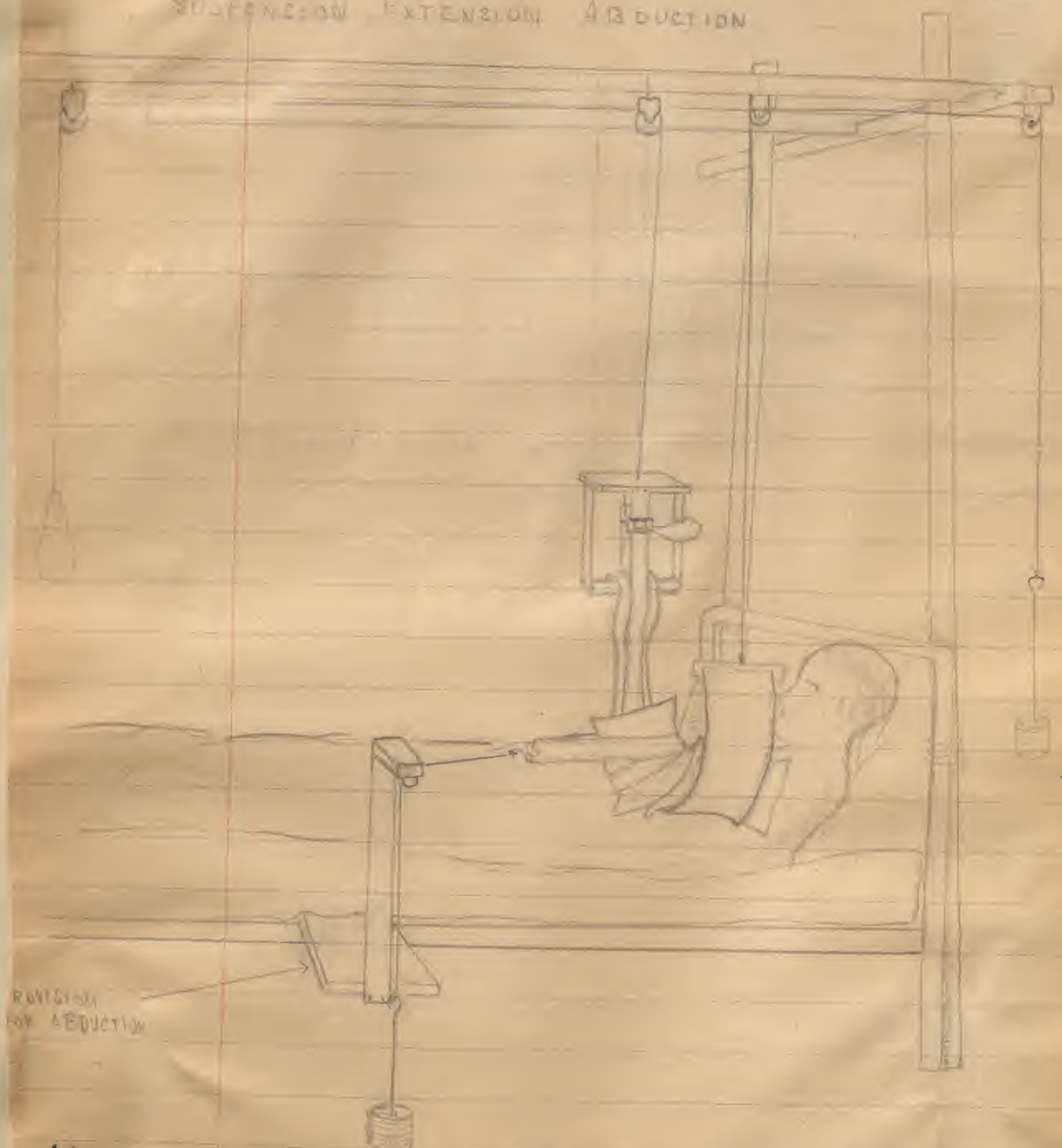

Abduction board as shown is placed between spring and mattress & held in place by pt.'s wgt.

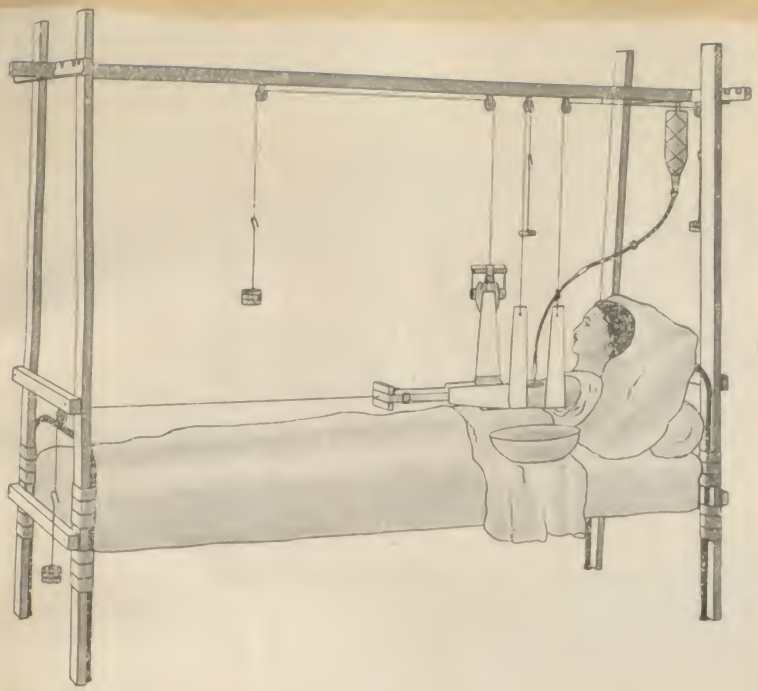

Fig. 4. — Fracture de l'humérus. Les bandes de suspension du bras sont en place. Application de l'irrigation continue.

SEE OTHER SIDE

Extension of humerus is obtained by means of Hennequin band or Barley-Caldwell strap not by glue as shown here.

ABDUCTION BOARD

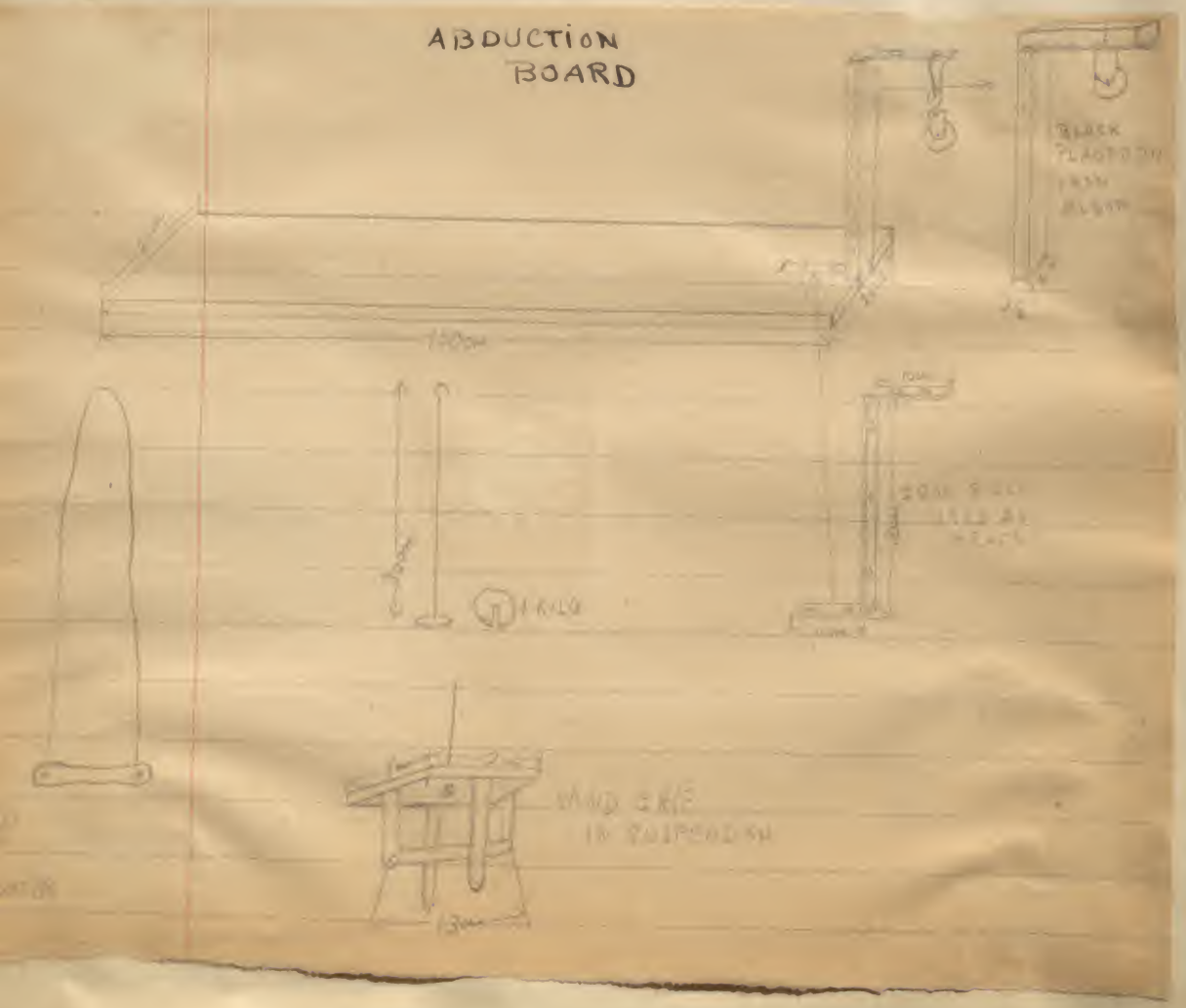

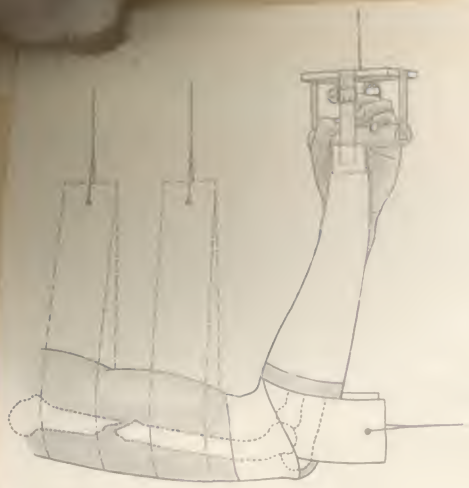

Fig. 5. — Extension obtenue au moyen d'une bande embrassant le coude au lieu d'une bande adhésive, dans le cas où l'emploi de cette dernière n'est pas possible. Le pansement de coton placé sous la bande, pour éviter une pression trop forte, n'a pas été figuré dans le dessin, afin de rendre le dispositif plus clair.

lancer exactement le poids du bras, de même que les poids servant à la suspension de l'avant-bras devraient correspondre à son poids. Si les poids sont plus lourds que l'avant-bras, les fragments auront également tendance à se recourber ; et, réciproquement, si ces poids sont trop légers, les fragments prendront une position angulaire en avant.

D'ordinaire, les bandes de suspension sont en finette doublée de toile non blanchie, ce qui leur donne de

Abduction board as shown is placed between spring and mattress + held in place by pt.'s wgt.

Extension of humerus is obtained by means of Hennequin band or Barley-Caldwell straps not by glue as shown here.

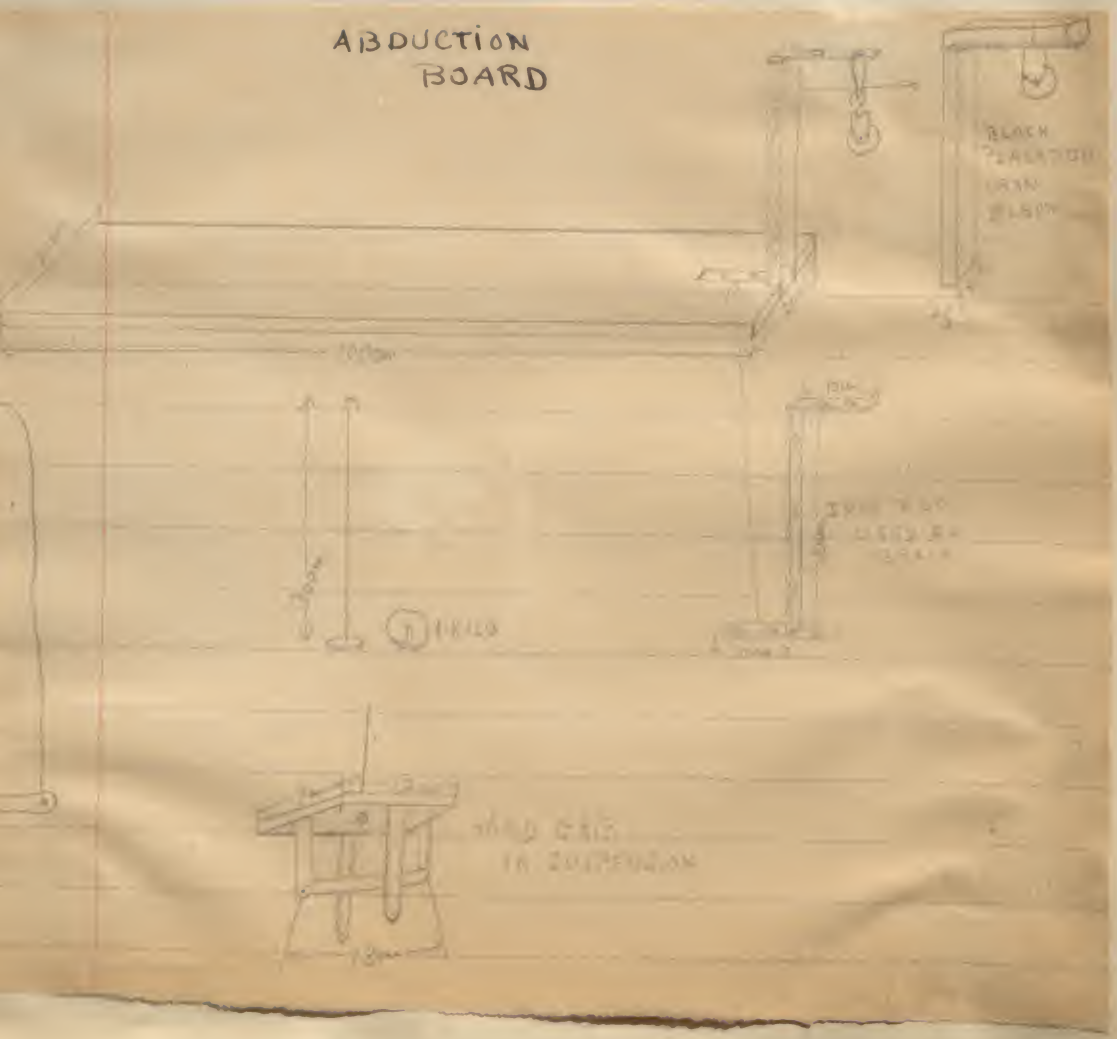

FRACTURE OF HUMERUS

SUSPENSION, EXTENSION ABDUCTION

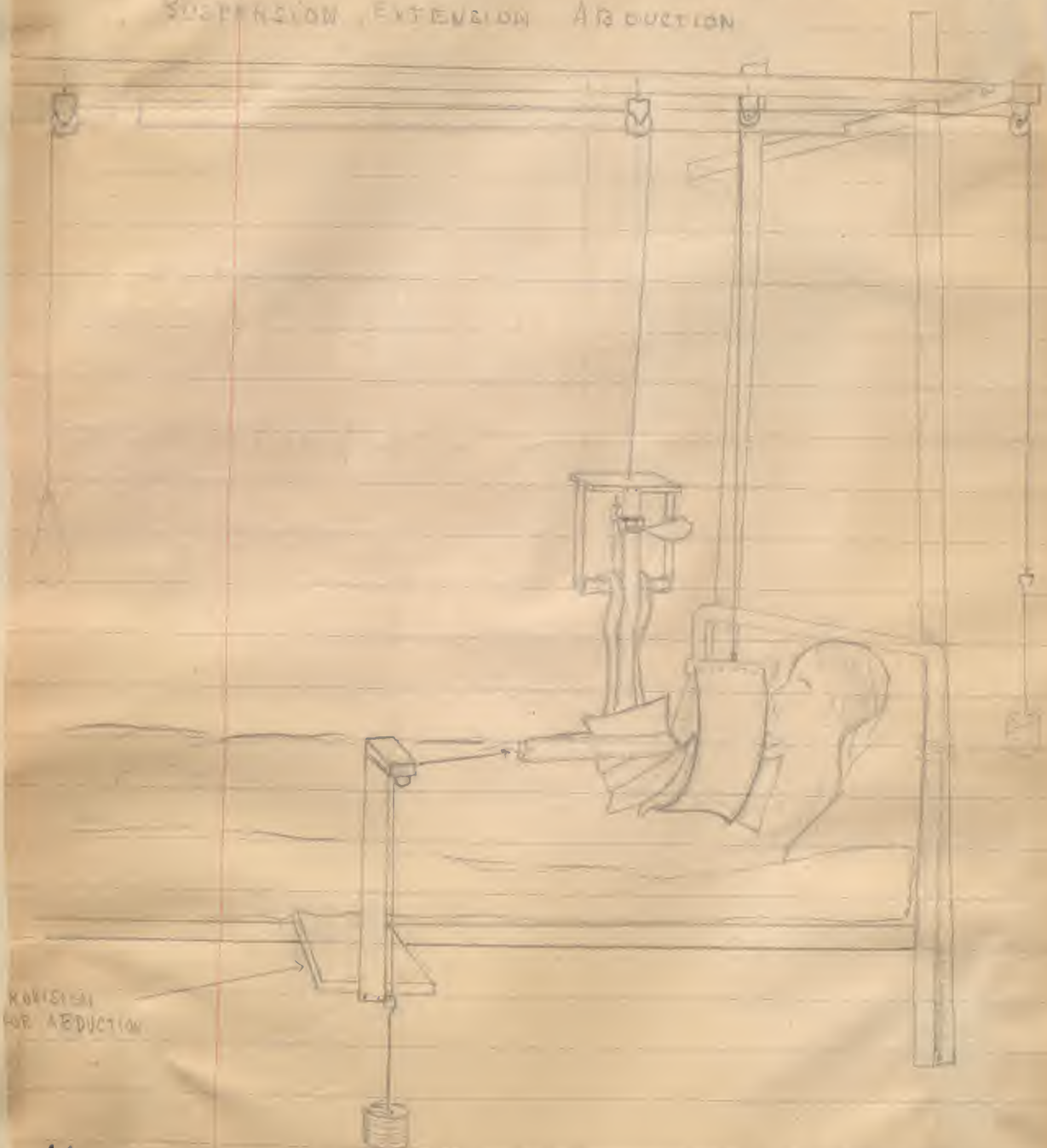

Abduction board as shown is placed between spring and mattress & held in place by pt.'s wgt.

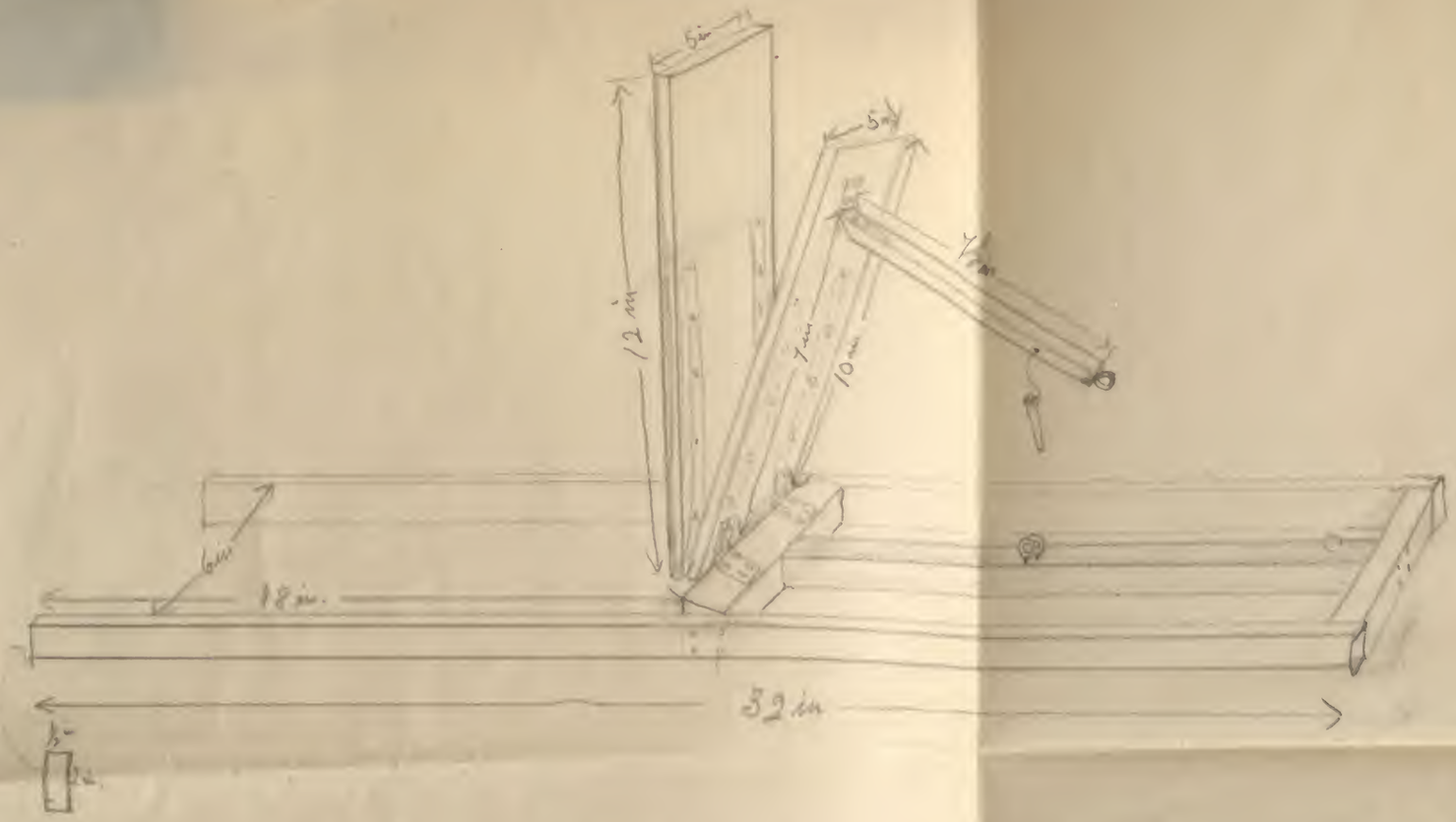
5in
5in
12 in
7 in
10 in
7 in
6in
18 in.
32 in
½"
½"

THE PRESBYTERIAN HOSPITAL

IN THE CITY OF NEW YORK

OFFICIAL NO. .....

NAME ..... DATE ..... HISTORY NO. .....

OPERATOR DR. ..... ASSISTANT DR. ..... POSITION OF PATIENT .....

OPERATION .....

..... DURATION .....

ANAESTHETIST ..... ANAESTHESIA ..... DURATION .....

THIS ONE INCH MARGIN RESERVED FOR BINDING. NO WRITING HERE.

A 123-5M-1-21

4

Fig. 15.— Quatre méthodes de traction employées pour fractures de jambe. (Pour description détaillée, voir p. 658.)

Il y a donc lieu, par conséquent, de la modifier pour chaque cas. Ainsi qu'il a déjà été exposé à propos des fractures du membre supérieur, il faut radiographier chaque fracture, au lit même du blessé, après que la réduction clinique en a été obtenue, ayant toujours pour objectif l'alignement des deux fragments sur le même axe.

Pour le traitement des fractures du fémur, on peut obtenir la traction de trois façons différentes :

1° Par bandes collées ;

2° Par traction exercée directement sur le squelette, comme par exemple avec la broche de Steinman ou la bande de Finochetto.

de tarla
plâtré p
après av
bande de
geur, on
en forme
C'est là,
tement d
est impos
Il est évi
blable pr
de la cuis

L'autre

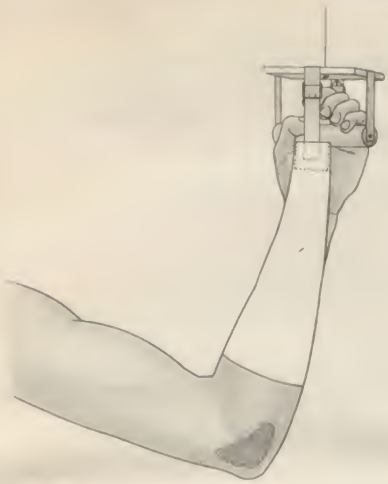

Fig. 6. — Détail de la suspension du bras pour plaies impliquant l'articulation du coude, montrant l'application des bandes adhésives sur l'avant-bras, et la poignée pour les doigts. Cette poignée est suspendue à la planchette par des bandes d'élastique et la tension de celles-ci est déterminée soit en raccourcissant, soit en allongeant les bandes adhésives au moyen de boucles.

moyenne, elles sont larg
de 30 cms. pour l'avant-
la cuisse.

Les bouts étroits des b
et fixés avec des épingl
facilement ajuster le su

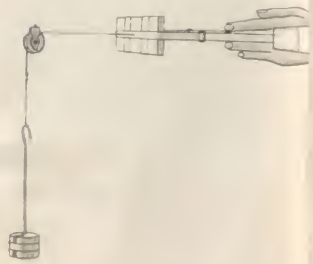

Fig. 8. — Détail de l'app
fractu

de faire de l'irrigation co
on peut employer une seu

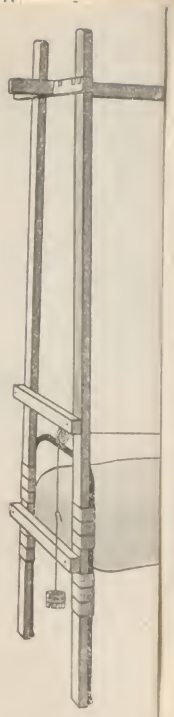

Fig. 7. — D

Extension is secured also with glove glued to fingers & rings in fingers. Counterextension is ~~well~~ better, secured c̄ glue if the fracture is low. The midway position or better supination should be maintained.

See case + picture - p. 33.

moyenne, elles sont larges au milieu de 12 cms. et longues de 30 cms. pour l'avant-bras et la jambe, et de 45 cms. pour la cuisse.

Les bouts étroits des bandes sont passés autour des barres et fixés avec des épingles de sûreté de manière à pouvoir facilement ajuster le support du membre. Lorsqu'il y a lieu

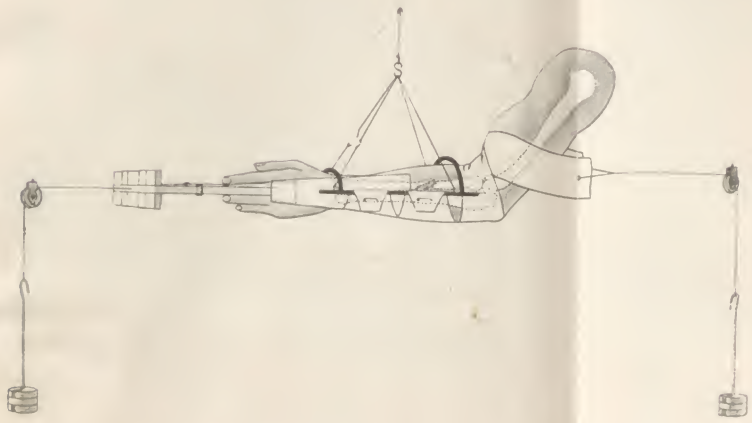

Fig. 8. — Détail de l'appareil d'extension et de suspension pour fractures de l'avant-bras.

de faire de l'irrigation continue ou des pansements humides, on peut employer une seule bande de toile caoutchoutée dont la largeur devra correspondre à la longueur du membre.

Extension is secured also with glove glued to fingers & rings in fingers. Counterextension is ~~well~~ better secured & glue if the fracture is low. The midway position or better supination should be maintained.

See case + picture - p. 33.

Fig. 12. — Utilisation de l'attelle droite et méthode de traction. Noter la disposition du cadre situé au pied du lit, l'abduction prononcée du membre, l'angle de la grande barre supportant le membre et ayant presque la même direction que lui, ainsi que la méthode du tourniquet pour obtenir la traction du membre dans l'attelle. — Remarquer également la bande plantaire destinée à éviter la chute du pied.

té avec la
dans leur

1. Blake. — *Arch. de Méd. et de Pharmacie militaires*, Paris, 1916, LXVI, 57.

rnière sont cloués deux morceaux
e ruban élastique. Aux deux bouts
res de ces élastiques est fixée une
guette ronde en bois. Elle doit être ajustée de
lle sorte que les doigts étendus puissent la sai-
r, afin de faire quelques exercices, mettant en jeu
élasticité des rubans. Ce dispositif est important,
n particulier dans les lésions du nerf radial.

La corde de suspension de l'avant-bras monte
lors et va passer dans une poulie fixée à l'une
es barres longitudinales situées au-dessus du
t. Cette barre, spéciale à l'avant-bras, est placée
20 cm. (ou plus) en dehors de la barre servant
la suspension directe du bras (fig. 6). On
btient par ce moyen la rotation externe du
ragment inférieur, résultat qui serait difficile à
cquérir si le bras et l'avant-bras étaient tous
deux fixés sur un même axe longitudinal.

La poulie soutenant l'avant-bras est placée,
d'ordinaire, suffisamment loin dans la direction
du pied du lit, pour donner au coude un angle
d'ouverture de 135° environ. Dans la suite, cet
angle peut être ramené à 90°; mais un angle
assez ouvert, donné dès le début, permet plus
facilement la traction.

Si la traction est nécessaire, elle peut être
obtenue de deux façons différentes :

a) L'emploi des bandes collées sur chaque
face latérale du bras est très efficace et donne une
onne traction du fragment osseux inférieur
(fig. 5). Egalement dans ce cas, on se sert d'une
planchette de traction, dépassant de 2 cm. la
largeur du coude, afin d'éviter la pression laté-

dans l'axe de
~~le cas de bles~~
placer une
pansement e
extension pr
suffisante p
l'humérus. P
faut encoura
les articulati
et des doigts
devront être

La questio
sera exposée
chaque fractu

Selon la ha
envisager, en
apporter aux
dessus :

1° Fracture
résections de

2° Fracture

3° Fracture
résections du

Hum
y compris

Les fractur
être traitées a
la suite des
faut pas emp
doit pas che

tations radiologiques recueillies au lit même du blessé.

Dans les fractures du tiers supérieur de la diaphyse humérale, en dessous du col chirurgical de l'humérus, la traction est en général nécessaire, mais dépasse rarement 2 kilogr. Elle peut être faite à l'aide de bandes collées. Quant à la suspension, on l'établit comme à l'ordinaire.

Les indications de l'abduction à donner au membre seront fournies par l'importance des lésions musculaires reconnues. En effet, si les in-

d'interrompre la traction deux fois par jour, afin de pouvoir pratiquer la mobilisation active et passive des petites articulations des doigts. La supination extrême est rarement nécessaire. Un degré un peu moindre suffit à empêcher l'union entre les deux os de l'avant-bras.

Dans les cas d'œdème considérable, il est parfois utile

de l'armée
décrite par
La parti
faire press
nières, aux
parallèles.
Ce dispo
remment p
gauche. A
sont unies
non rectilig
tion de la r
à sa partie

nt-bras en posi-
à l'aide du gant,
des collées.
at des blessures
toutes les frac-

rnière sont cloués deux morceaux
e ruban élastique. Aux deux bouts
bres de ces élastiques est fixée une
guette ronde en bois. Elle doit être ajustée de
lle sorte que les doigts étendus puissent la sai-
r, afin de faire quelques exercices, mettant en jeu
élasticité des rubans. Ce dispositif est important,
n particulier dans les lésions du nerf radial.

La corde de suspension de l'avant-bras monte
lors et va passer dans une poulie fixée à l'une
es barres longitudinales situées au-dessus du
t. Cette barre, spéciale à l'avant-bras, est placée
20 cm. (ou plus) en dehors de la barre servant
la suspension directe du bras (fig. 6). On
btient par ce moyen la rotation externe du
ragment inférieur, résultat qui serait difficile à
equérir si le bras et l'avant-bras étaient tous
deux fixés sur un même axe longitudinal.

La poulie soutenant l'avant-bras est placée,
d'ordinaire, suffisamment loin dans la direction
du pied du lit, pour donner au coude un angle
d'ouverture de 135° environ. Dans la suite, cet
angle peut être ramené à 90°; mais un angle
assez ouvert, donné dès le début, permet plus
facilement la traction.

Si la traction est nécessaire, elle peut être
obtenue de deux façons différentes :

a) L'emploi des bandes collées sur chaque
face latérale du bras est très efficace et donne une
onne traction du fragment osseux inférieur
(fig. 5). Egalement dans ce cas, on se sert d'une
planchette de traction, dépassant de 2 cm. la
largeur du coude, afin d'éviter la pression laté-

dans l'axe de
le cas de blec
placer une
pansement e
extension pr
suffisante p
l'humérus. P
faut encoura
les articulati
et des doigts
devront être
La questio
sera exposée
chaque fractu
Selon la ha
envisager, en
apporter aux
dessus :
1° Fracture
résections de
2° Fracture
3° Fracture
résections du
Hum
y compris
Les fractur
être traitées a
la suite des
faut pas emp
doit pas che

que l'on puisse attendre de cette intervention c'est l'ankylose, bien que ce soit très souvent le « bras en fléau » que l'on observe.

Enfin, dans les plaies situées bas, on obtient une très bonne traction en se servant d'un gant, ainsi que le montre la figure 10. La main est d'abord copieusement enduite de colle, puis recouverte d'un gant de coton blanc, portant à l'extrémité de chacun des doigts un petit anneau métallique. La traction est faite par l'intermédiaire des doigts et demande un poids de 1 kilogr. 1/2 environ.

Il faut prendre grand soin d'interrompre la traction deux fois par jour, afin de pouvoir pratiquer la mobilisation active et passive des petites articulations des doigts. La supination extrême est rarement nécessaire. Un degré un peu moindre suffit à empêcher l'union entre les deux os de l'avant-bras.

Dans les cas d'œdème considérable, il est parfois utile

du genou peut être modifié
métallique pour suspensi
page 656.)

nt-bras en posi-
à l'aide du gant,
des collées.
at des blessures
toutes les frac-

causes les
ces blessu
Toutes l
qu'elles s
figure 11,
d'attelles h
de chacune
tement de
ticulier. L
de cette p
apportée p
de l'armée
décrite par
La parti
faire press
nières, aux
parallèles.
Ce dispo
remment p
gauche. A
sont unies
non rectilig
tion de la r
à sa partie

la diaphyse hum
sures basses du

tations radiologiques recueillies au lit même du blessé.

Dans les fractures du tiers supérieur de la diaphyse humérale, en dessous du col chirurgical de l'humérus, la traction est en général nécessaire, mais dépasse rarement 2 kilogr. Elle peut être faite à l'aide de bandes collées. Quant à la suspension, on l'établit comme à l'ordinaire.

Les indications de l'abduction à donner au membre seront fournies par l'importance des lésions musculaires reconnues. En effet, si les in-
[illegible] et dorsales sont dé-


B

truites, il y aura lieu de donner plus d'abduction au membre que si ces insertions étaient conservées.

D'une manière générale ces fractures demandent une abduction de 60°. On y parvient très simplement ainsi qu'il est indiqué figure 7.

L'appareil consiste en une planch

Fig. 7. — Méthode simple permettant d'obtenir l'abduction et la traction du bras à l'aide d'une planche non rabotée, glissée entre le matelas et le sommier, et maintenue en place par le poids même du blessé. (Voir le texte « Humérus », tiers supérieur.)

il est donc préférable de ne pas la couper.

Chaque montant vertical mesure 2 mètres de hauteur. La longueur des barres transversales dépend de la largeur du lit employé. Pour les lits du Service de Santé, la barre supérieure mesure 1 mètre, et la barre inférieure 75 cm.

obtenu ; de plus, pour le traitement de la blessure elle-même, on acquiert ainsi toutes les plus grandes facilités.

Par cette méthode, soigneusement contrôlée par l'examen radiologique pratiqué au lit même du blessé, on obtient sans peine l'alignement parfait des fragments osseux.

L'appareil de suspension consiste en deux sortes de cadres (un à chaque extrémité du lit du blessé) reliés l'un à l'autre au-dessus de ce lit par deux, ou même plusieurs longues barres parallèles et longitudinales.

Chaque cadre est constitué par deux montants réunis entre eux par deux barres transversales. La barre inférieure est placée au niveau du bord supérieur du matelas. La barre supérieure est fixée très haut sur le montant, pas trop haut toutefois, afin de ne pas fendre le bois en plaçant les vis. Cette barre transversale supérieure est munie, à sa partie supérieure, d'encoches destinées à recevoir les grandes barres longitudinales.

Fig. 13. — Dispositif pour fracture du tiers supérieur du fémur, où a été employée la broche de Steinman. Noter la flexion du genou, l'abduction et la rotation externe du membre.

La bande plantaire contre la chute du pied n'a pas été figurée ici, pour plus de clarté du dessin. (Voir le texte page 657.)

le jambe. L'attelle est courbée à 135° envi-
milieu, est représentée comme attachée trop
hauteur du genou, environ, on parvient à
exte page 658.)

puis à attendre le début de la réunion des fragments. Le siège de la fracture est encore fibreux et flexible. On retire alors l'attelle droite, pour la remplacer par une attelle de Hodgens courbée à 110° environ. Lorsque le membre est fléchi dans cette attelle, le mouvement de flexion ne se fera pas au genou (qui sera devenu raide), mais au point de fracture, et les fragments devront être remis, bout à bout. Un enroulement de bande au niveau du mollet maintient alors l'attelle, par l'extrémité distale de laquelle se fait ensuite la traction. Pour avoir un bon résultat, il faut pratiquer une forte traction avant de changer d'attelle, afin que les muscles se trouvent suffisamment étirés, et que tout chevauchement soit corrigé.

chetto. E
sous anes
qu'en rég
d'infectio
assez pr
néum. Il
bande pla

La figu
Smith, u
et utile. I
les dime
pied. Dan
dix encoc
vant son
tudinale a

La tête
viendra
extrémité
reçoit, à
garnit d
La barre

on de la

être em-
kilogr.
e et dé-

la partie
l'autre
quin ne
la posi-
l'abduc-
nsertion
à peine
en rota-

vant que
oche de

acé dans
propriée,
uis, sus-
externe;
t utilisé

Fractures du tibia et du péroné.

Toutes les plaies et fractures de la jambe se guérissent beaucoup plus vite, si le membre est mis en suspension. C'est là une règle générale. Pour cela, on se sert d'une attelle de Hodgens courbée à 135°, disposée ainsi que le montre la figure 14. La jambe placée au milieu de l'attelle repose sur les bandes ordinaires (v. fig. 4). L'appareil est suspendu par le trolley précédemment décrit. La contre-extension est obtenue par l'in-

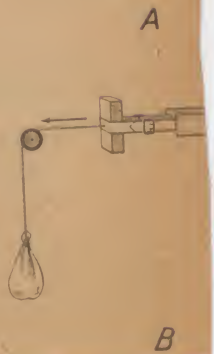

6. — Dispositif de suspension pour fracture
mérus. Remarquer l'usage de trois barres longitu-
les, la plus externe des trois servant à soutenir
nt-bras, en maintenant le fragment inférieur de
mérus en rotation externe. (Se reporter au texte
mérus », observations générales.)

le jambe. L'attelle est courbée à 135° envi-
milieu, est représentée comme attachée trop
hauteur du genou, environ, on parvient à
exte page 658.)

puis à attendre le début de la réunion des fragments. Le siège de la fracture est encore fibreux et flexible. On retire alors l'attelle droite, pour la remplacer par une attelle de Hodgens courbée à 110° environ. Lorsque le membre est fléchi dans cette attelle, le mouvement de flexion ne se fera pas au genou (qui sera devenu raide), mais au point de fracture, et les fragments devront être remis, bout à bout. Un enroulement de bande au niveau du mollet maintient alors l'attelle, par l'extrémité distale de laquelle se fait ensuite la traction. Pour avoir un bon résultat, il faut pratiquer une forte traction avant de changer d'attelle, afin que les muscles se trouvent suffisamment étirés, et que tout chevauchement soit corrigé.

chetto. E
sous anes
qu'en rég
d'infectio
assez pro
néum. Il
bande pla

La figu
Smith, u
et utile. I
les dimen
pied. Dan
dix encoc
vant son
tudinale a

La tête
viendra
extrémité
reçoit, à
garnit d'
La barre

on de la

être em-
kilogr.
e et dé-

la partie
l'autre
quin ne
la posi-
l'abduc-
nsertion
à peine
en rota-

vant que
oche de

acé dans
propriée,
uis, sus-
externe;
t utilisé

Fractures du tibia et du péroné.

Toutes les plaies et fractures de la jambe se guérissent beaucoup plus vite, si le membre est mis en suspension. C'est là une règle générale. Pour cela, on se sert d'une attelle de Hodgens courbée à 135°, disposée ainsi que le montre la figure 14. La jambe placée au milieu de l'attelle repose sur les bandes ordinaires (v. fig. 4). L'appareil est suspendu par le trolley précédemment décrit. La contre-extension est obtenue par l'in-

Fig. 6. — Dispositif de suspension pour fracture d'humérus. Remarquer l'usage de trois barres longitudinales, la plus externe des trois servant à soutenir l'avant-bras, en maintenant le fragment inférieur de l'humérus en rotation externe. (Se reporter au texte « Humérus », observations générales.)

dans le berceau pour avant-bras. Elles sont faites de deux épaisseurs de mousseline non blanchie. Elles existent en deux dimensions, les plus petites mesurant 40 × 12 cm. et les plus grandes 60 × 20 cm. Avec les pansements humides, on utilise des bandes semblables en tissu caoutchouté, double face.

B, Forme des bandes de traction à coller sur la peau. Elles se font en finette en deux dimensions : Petite taille pour l'avant-bras et la plante du pied, 25 × 8, non compris les rubans. Grande taille pour la jambe, 40 × 15.

trolley (fig. 3) consistant en une tringle de fer sur laquelle vient glisser, à l'aide de poulies, une pièce de bois.

Cette tige de fer a 10 mm. de diamètre, et 90 cm. de longueur. L'une de ses extrémités est courbée deux fois à angle droit, en forme de baïonnette. Elle est destinée à être fixée par quelques tours de bande de toile à l'une des barres longitudinales, après que l'autre extrémité rectiligne a été engagée dans un trou percé dans une pièce de fer recourbée à angle droit et vissée elle-même à la barre longitudinale.

A cette tige est suspendue, par l'intermédiaire de deux poulies, une barre de bois de 40 cm. de longueur environ ; ces deux poulies, destinées à rouler sur la tringle, sont fixées à la face supérieure de cette pièce de bois, alors que la face inférieure porte trois poulies pour la suspension du membre. On peut employer, soit des poulies à crochet, soit des poulies à vis. Ce dernier modèle nous semble être plus facilement ajustable.

Les poids sont ordinairement de 500 gr. Toutefois pour un réglage précis, et lorsque les poids

dans le berceau pour avant-bras. Elles sont faites de deux épaisseurs de mousseline non blanchie. Elles existent en deux dimensions, les plus petites mesurant 40 × 12 cm. et les plus grandes 60 × 20 cm. Avec les pansements humides, on utilise des bandes semblables en tissu caoutchouté, double face.

B, Forme des bandes de traction à coller sur la peau. Elles se font en finette en deux dimensions : Petite taille pour l'avant-bras et la plante du pied, 25 × 8, non compris les rubans. Grande taille pour la jambe, 40 × 15.

trolley (fig. 3) consistant en une tringle de fer sur laquelle vient glisser, à l'aide de poulies, une pièce de bois.

Cette tige de fer a 10 mm. de diamètre, et 90 cm. de longueur. L'une de ses extrémités est courbée deux fois à angle droit, en forme de baïonnette. Elle est destinée à être fixée par quelques tours de bande de toile à l'une des barres longitudinales, après que l'autre extrémité rectiligne a été engagée dans un trou percé dans une pièce de fer recourbée à angle droit et vissée elle-même à la barre longitudinale.

A cette tige est suspendue, par l'intermédiaire de deux poulies, une barre de bois de 40 cm. de longueur environ ; ces deux poulies, destinées à rouler sur la tringle, sont fixées à la face supérieure de cette pièce de bois, alors que la face inférieure porte trois poulies pour la suspension du membre. On peut employer, soit des poulies à crochet, soit des poulies à vis. Ce dernier modèle nous semble être plus facilement ajustable.

Les poids sont ordinairement de 500 gr. Toutefois pour un réglage précis, et lorsque les poids

moyenne, elles sont larg
de 30 cms. pour l'avant-
la cuisse.

Les bouts étroits d
et fixés avec de
facilement ajuste

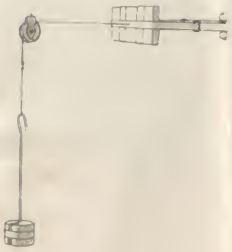

Fig. 8. — Détail de

de faire de l'irrigati
on peut employer u
le longeur devra cor

puis à attendre le
début de la réunion
des fragments. Le

dans le berceau pour avant-bras. Elles sont faites de deux épaisseurs de mousseline non blanchie. Elles existent en deux dimensions, les plus petites mesurant 40 × 12 cm. et les plus grandes 60 × 20 cm. Avec les pansements humides, on utilise des bandes semblables en tissu caoutchouté, double face.

B, Forme des bandes de traction à coller sur la peau. Elles se font en finette en deux dimensions : Petite taille pour l'avant-bras et la plante du pied, 25 × 8, non compris les rubans. Grande taille pour la jambe, 40 × 15.

le jambe. L'attelle
milieu, est représen
hauteur du genou,
exte page 658.)

on de la
être em-
kilogr.
e et dé-

la partie
l'autre
quin ne
la posi-
l'abduc-
nsertion
à peine
en rota-

vant que
oche de

acé dans
propriée,
uis, sus-
externe;
t utilisé

de fle
venu
ment
enrou
maint
de la
un bo
tion
muscl
étirés
corrig

Frac

Tou
la jam
vite,
pensic
Pour
de Ho
ainsi
jambe
repose
(v. fig.
le troll
contre-

chetto.
sous ane
rég

trolley (fig. 3) consistant en une tringle de fer sur laquelle vient glisser, à l'aide de poulies, une pièce de bois.

Cette tige de fer a 10 mm. de diamètre, et 90 cm. de longueur. L'une de ses extrémités est courbée deux fois à angle droit, en forme de baïonnette. Elle est destinée à être fixée par quelques tours de bande de toile à l'une des barres longitudinales, après que l'autre extrémité rectiligne a été engagée dans un trou percé dans une pièce de fer recourbée à angle droit et vissée elle-même à la barre longitudinale.

A cette tige est suspendue, par l'intermédiaire de deux poulies, une barre de bois de 40 cm. de longueur environ; ces deux poulies, destinées à rouler sur la tringle, sont fixées à la face supérieure de cette pièce de bois, alors que la face inférieure porte trois poulies pour la suspension du membre. On peut employer, soit des poulies à crochet, soit des poulies à vis. Ce dernier modèle nous semble être plus facilement ajustable.

Les poids sont ordinairement de 500 gr. Toutefois pour un réglage précis, et lorsque les poids

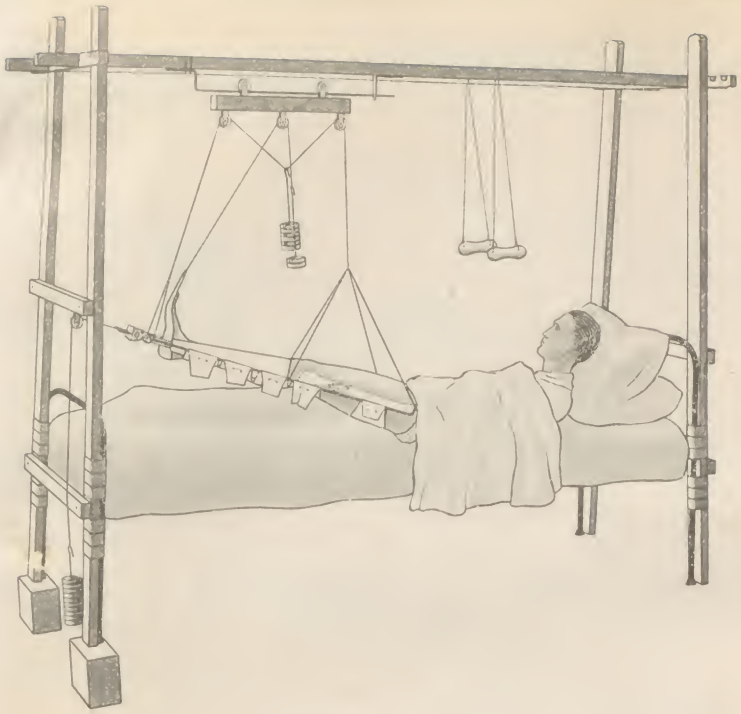

Fig. 10. — Traitement d'une fracture de la partie inférieure du fémur au moyen d'une forme modifiée de l'attelle de Thomas.

See over.

If fracture is high the leg is put up in abduction to follow superior fragment out.

For illustrative cases see pp. 36, 37, 38, 39, 40.

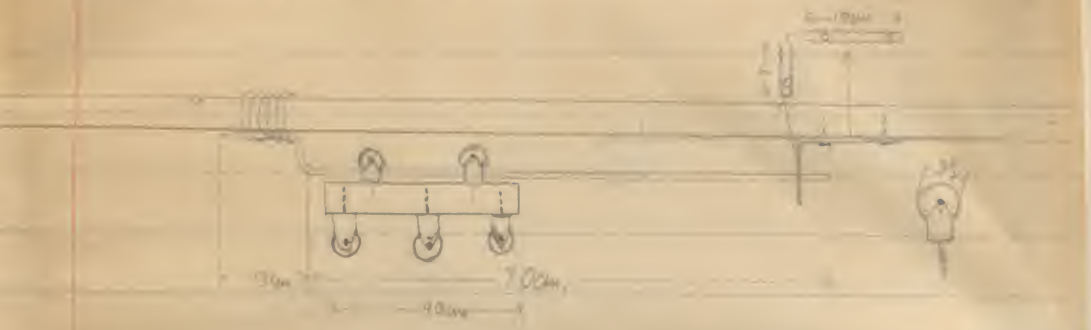
70cm.
90cm

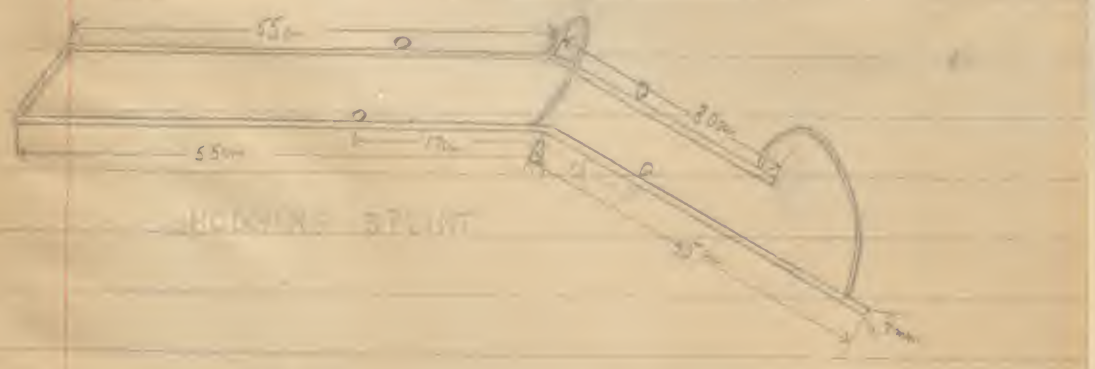
55cm
55cm
80cm
45°

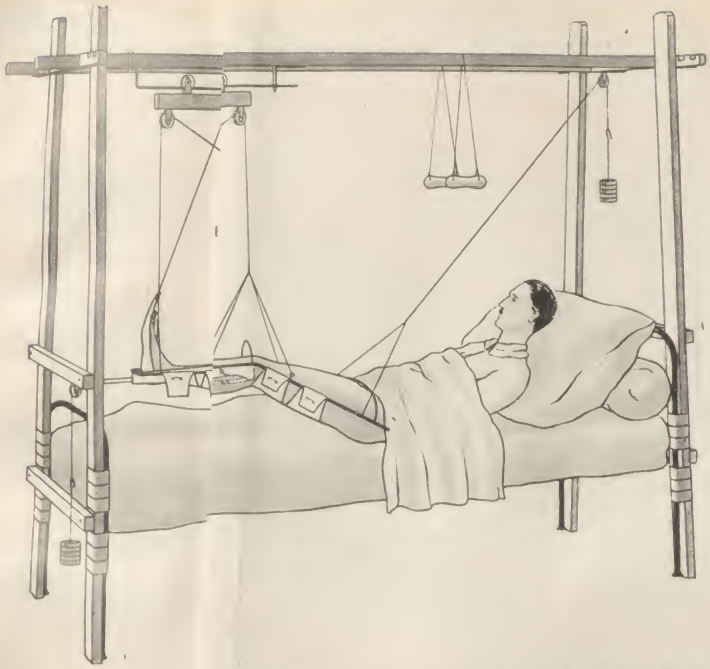

Fig. 12. — Dispos de l'appareil pour le traitement de fractures du tibia et du roné. — Le dessinateur a oublié d'indiquer la planchette d'écement des bandes d'extension.

See over

Apparatus for Correction of toe drop and exercise of leg muscles.
Attachment is made to the foot of the bed by means of a cord. Resistance to the movements of the foot is made by means of a hinge spring, the intensity of which pressure may be regulated by advancing the prop (A).

When this apparatus was applied to patient shown in picture he had no control of movement at the ankle due to disuse. In two weeks a certain degree of voluntary motion had returned.

Apparatus for Correction of Toe Drop
Hinged foot ~~pade~~ piece is drawn upward by elastic. The whole is wired to a posterior moulded plaster splint extending from below the knee to the ankle. The plaster splint was made on a heavy wire frame and small wires incorporated which were afterward fastened to the leg pieces of the apparatus.
The patient walked on crutches & even put some wgt. on foot.

courbes sont resserrées dans
exercée sur l'extrémité inférieure du
tension est obtenue par la pression de l'

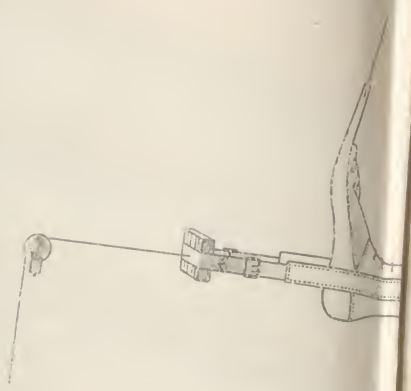

Fig. 13. — Détails d'application de la guêtre p
la bande adhésive pour empêcher la chute d
sement de coton placé sous la guêtre n'a p
dessin afin de rendre le dispositif plus clair

de l'appareil contre l'ischion. L'attelle
et le membre supporté par les bandes pas
d'une barre à l'autre, on peut le porter dans
direction sans déranger la position relative

Apparatus for Correction of toe drop and exercise of leg muscles.
Attachment is made to the foot of the bed by means of a cord. Resistance to the movements of the foot is made by means of a hinge spring, the intensity of which pressure may be regulated by advancing the prop (A).

When this apparatus was applied to patient shown in picture he had no control of movement at the ankle due to disease. In two weeks a certain degree of ~~v~~ voluntary motion had returned.

Apparatus for Correction of Toe Drop
Hinged foot ~~piece~~ piece is drawn upward by elastic. The whole is wired to a posterior moulded plaster splint extending from below the knee to the ankle. The plaster splint was made on a heavy wire frame and small wires incorporated which were afterward fastened to the leg pieces of the apparatus.
The patient walked on crutches & even put some wgt. on foot.

For case see pp. 30, 31.

ELEVATING APPARATUS

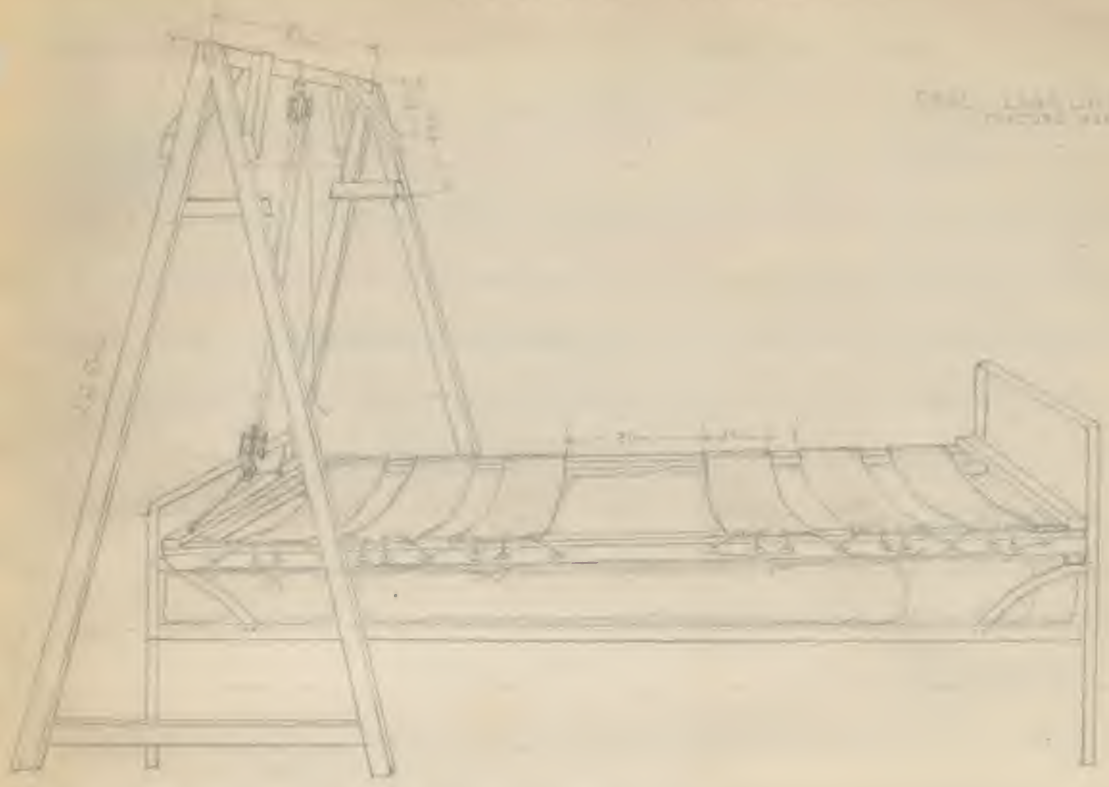



Dr. Allison.

N.A.S.M.

APPARATUS OF DELBET S.S.

PLASTER SPLINTS - LEG

CIRCULAR LEG PIECE

[A]



Lateral leg pieces trimmed over.

[B]

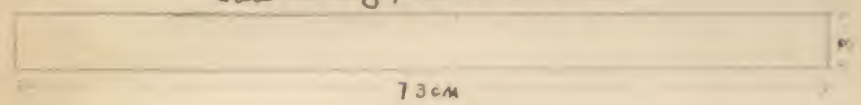

ANKLE PIECE

[C]



2nd ANKLE PIECE

[D]



Layers of crinolin 10 pieces thick + folded over rather than cut.

Crinolin pieces seen in use at the front for plaster work, by Dr. Blake + Captain Allison. They reported that they saw men walking, who had broken fibula + tibia, three days after the application of the plaster + some who had used the same for 3 months without a bed sore appearing.

See page 124 of "Appareillage dans le Traitement de Guerre".

Oct 29, 1917

Telephone Probe of Dr. Bulkley - (as used by him in N.Y.)

Apparatus - Two ear pieces like wireless receiver - Each contains an electromagnet ~~of~~ wound with fine wire (copper) of 1500 ohms resistance making 3000 ohms. Indifferent electrode = rod of carbon to be placed in mouth, rectum, ~~or~~ vagina (this obviates skin resistance). Other electrode - large sewing needle ~~shelaced~~ up to within ½ cm. of point. (Probe may be substituted)

On passing electrode into flesh or wound the contact with tissues gives a little click. On touching metal (including lead) one hears a rasping sound plainly. Take care not to be near a large dynamo or magnet ~~or iron~~ or not on iron bed.

Dr. Bulkley finds the same instrument with 1200 ohms resistance (in all) is most satisfactory as this gives no click on meeting tissue but only metal.

Glue. Lindoit.

Consistency is obtained. Before use it must ~~by~~ be heated. The principle advantage of this glue over Feusner's is that there is no necessity to shave the p[illegible] and it comes off ē water. It is more messy however and I find ~~it~~ less satisfactory.

Solutions in use for Dressings – Dr. Blake

			gm-cc.
1.	β naphthol	β. naphthol	1
		Sod. Hydroxide	1
		H_2O	1000

			gm:cc	
2.	Quinine	Quinine Hydrochloride	1	used only with acetic as see below.
		NaCl	8	
		H_2O	1000	

			gm. cc PE	P..
3.	Sodium Bicarb.	Sodium bicarb.	10	40
		NaCl	~~9~~ 8	
		H_2O	1000	

4.	Acetic	Acetic acid (90%)	5
		NaCl	8
		H_2O	1000.

(To make up the much used Acetic & Quinine combine two above formulae making same strength ie Quinine 1 gm. – Acetic 5 gms. Nacl 8.

5. Carrel Modification of Dakins Solution – Dauphresne Formula
Preparation of same below.
(Method employed at Carrel Hospital Compiègne.)

			gm-cc
(1) Accurately weigh.		Chloride of lime $(Ca(OCl)_2)$	200
		Dried Carbonate of Soda Na_2CO_3	100 = 200
		Bicarbonate " " $NaHCO_3$	80

(2.) Place Chloride of lime in 12 L. bottle add 5 L. ordinary water and shake several times well at intervals + allow to stand over night.

Oct 29, 1917

Telephone Probe of Dr. Bulkley - (as used by him in N.Y.)

Apparatus - Two ear pieces like wireless receiver - Each contains an electromagnet ~~of~~ wound with fine wire (copper) of 1500 ohms resistance making 3000 ohms. Indifferent electrode = rod of carbon to be placed in mouth, rectum, or vagina (this obviates skin resistance). Other electrode - large sewing needle shelaced up to within ½ cm. of point. (Probe may be substituted)

On passing electrode into flesh or wound the contact with tissues gives a little click. In touching metal (including lead) one hears a rasping sound plainly. Take care not to be near a large dynamo or magnet ~~or iron~~ & not on iron bed.

Dr. Bulkley finds the same instrument with 1200 ohms resistance (in all) is most satisfactory as this gives us click on meeting tissue but only metal.

Glue. Lindoit.

GLUE No 2

Common glue	200 gr.
Water	200 "
Glycerine	8 "
Calcium chloride	4 "
Thymol	4 "

Above is I believe what Dr. Lindoit uses in his treatment of fractures. It must be boiled in double boiler till desired consistency is obtained. Before use it must ~~by~~ be heated. The principle advantage of this glue over Neuman's is that there is no necessity to shave the p[illegible] and it comes off ē water. It is more messy however and I find it less satisfactory.

Solutions in use for Dressings – Dr. Blake

			gm-cc.
1.	β naphthol	β. naphthol	1
		Sod. Hydroxide	1
		H_2O	1000

			gm:cc	
2.	Quinine	Quinine Hydrochloride	1	used only with acetic as see below.
		NaCl	8	
		H_2O	1000	

			gm. cc PE	P..
3.	Sodium Bicarb.	Sodium bicarb.	10	40
		NaCl	~~7~~ 8	
		H_2O	1000	

4.	Acetic	Acetic Acid (90%)	5
		NaCl	8
		H_2O	1000.

(To make up the much used Acetic & Quinine combine two above formulae making same strength i.e Quinine 1 gm. Acetic 5 gms. Nacl 8.

5. Carrel Modification of Dakins Solution – Dauphresne Formula
Preparation of same below.
(Method employed at Carrel Hospital Compiègne.)

			gm cc
(1) Accurately weigh.		Chloride of lime $(Ca(OCl)_2)$	200
		Dried Carbonate of Soda Na_2CO_3	100 = 200
		Bicarbonate " " $NaHCO_3$	80

(2.) Place Chloride of lime in 12 L. bottle add 5 L. ordinary water and shake several times well at intervals + allow to stand over night.

(3.) Dissolve the Carbonate & Bicarbonate of soda in 5 P. of ordinary cold water

(4.) Turn all the solution of soda salts into the bottle of Chloride of lime. Shake vigorously 1 min. & allow to stand to allow carbonate of lime to settle to the bottom

5) In about ~~a~~ ½ hour siphon of the clear liquid and filter thru filter paper in order to obtain a perfectly clear ~~liquid~~ solution. This should be kept in a dark place. (Here solution is placed in large flask and from time to time is stirred up and poured into vessel where it & the salt settles out and fluid is taken off from surface without filtering. 3 drops of Pot. permanganate is put in bottle before sending to ward.

Solution is now ready for surgical use. It contains about ½ % Sodium Hypochlorite with a small quantity of the neutral salts of soda ~~am~~.
It is markedly isotonic to blood serum.

5

Test.

20 cc. sol. in beaker.
Few centigrams powdered Phenol sulphophthalein.
Shake - Liquid should remain clear & colorless.
Red tinge indicates an appreciable amt. of free alkali or an incomplete reaction with the carbonate charged, to some fault in the ~~t~~ technique of preparation.

Standardization of Solution.

10 cc. Sol.

10 cc. distilled water

2 gms. KI.

2 cc Acetic Acid

Pour into this solution a decinormal (2.48%) solution of hyposulphite of soda in quantity just sufficient to decolorize it. If N. be the number of cc. of hyposulphite used. the percentage of hypochlorite in the solution will be given by the equation:

$$\% = N \times 0.03725$$

When complete add enough 5% permanganate to color pale mauve.

Errors to be avoided.

Never heat the solution

If, in an emergency it is necessary to use a mortar to prepare the Chloride of lime. Do not use anything with it but water. Never add soda salts.

$$Ca(ClO)_2 + Na_2CO_3 = CaCO_3 + 2NaOCl$$

$$CaCl_2 + Na_2CO_3 = CaCO_3 + 2NaCl$$

B.I.P. - Lancet Aug 12, 1916

Rutherford Morrison - Bipp

Procedure.

(1.) Under anaesthetic cover wound with gauze wrung out in 1-20 carbolic - Clean skin c̄ same.

(2) Open wound freely + inspect - Cleanse cavity with dry sterile gauze, Volkmanns spoon etc. + remove FBs.

(3) Mop surrounding skin + wound cavity with methylated spirit (Cotton wool on forceps.)

(4) Fill up the whole wound with the paste described below, dress with sterile gauze + cover with pad absorbent + bandage. No change of dressing required for days or weeks unless pain or constitutional disturbance appears.

If discharge comes through the stained pt. must be soaked in spirit and a gauze dressing wrung out in the same be applied as a further ~~dressing~~ covering.

Advantages are most striking in cases of compound fracture of long bones.

Redressing - Remove old dressing. cover wound with a dossil of wool soaked in spirit and wipe off discharge from skin c̄ cotton wool + spirit. Plaster wound and small area surrounding skin with paste, cover c̄ gauze pad + bandage.

The above was used by Morrison in old cases - not fresh. Where there is danger of gangrene he advises leaving the wound wide open + filled c̄ Bipp.

~~Much~~ some of the bipp is discharged + a small sinus forms which in majority of cases heals quickly. "In the majority of cases the mass appears to be slowly absorbed."

40 cases treated without changing a dressing unexpectedly

and always getting good results. - No stitch sutures appear about catgut.

The paste - Bipp.
Bismuth subnitrate 1 oz. by wgt.
Iodoform 2 " " "
liq. paraffin q.s. to make a thick paste
Application with two egg spoons.

Bipp - used at 6 Am Piccini by Dr. Schel. -
(1) Large superficial wound of L. buttock - excellent condition. Bacterial count fell to 8 in a field with irrigation by Dakins.

Wound smeared with Bipp and closed. Edges not freshened. Result - brown thick discharge continued to be exuded for some time. 2/3 of suture line held. 1/3 gapped and after a period of 6 weeks I found there was a sinus under the suture line. On opening this along the line with a pair of scissors I found a very thick hard cicatrix which showed no signs of softening or change after repeated curettings & dressings

(2) + (3) Two stumps were altered, flaps being brought down and sutured after application of Bipp.

On entrance
Carrant May 10, 1917.
Right Humerus.

Carrant. - wound May 6.

May 7. - debridement, esquillectomy + disinfection

May 10. admitted - X ray taken. Wound postero lateral large + open

June 7. F.B. removed - Reported bone fragment attached to bone - followed by 1 week high temperature

June, July + August - occasional exaccerbations of temperature no union
muscles became hard + infiltrated

Aug. 29. Four sequestra removed - see numbers next page. ~~in~~
incision was through posterior wound. There followed
a fairly continuous fever.

Sept 13. Incision of abscess pointing internally



Muscles were very hard + infiltrated
Carrel tubes placed internally and externally. The bone fragments shown in X ray No 3. could be felt but were solidly attached + hung left.
Temperature dropped. Wounds granulated over. Beginning union.

Nov. 3. Arm taken down - consolidation.

P. Grant. Aug 17, 1917
Sequestra (1), (2), (3), (4) were removed

Langlois #90. - Fracture of L. innominate bone & head of femur.

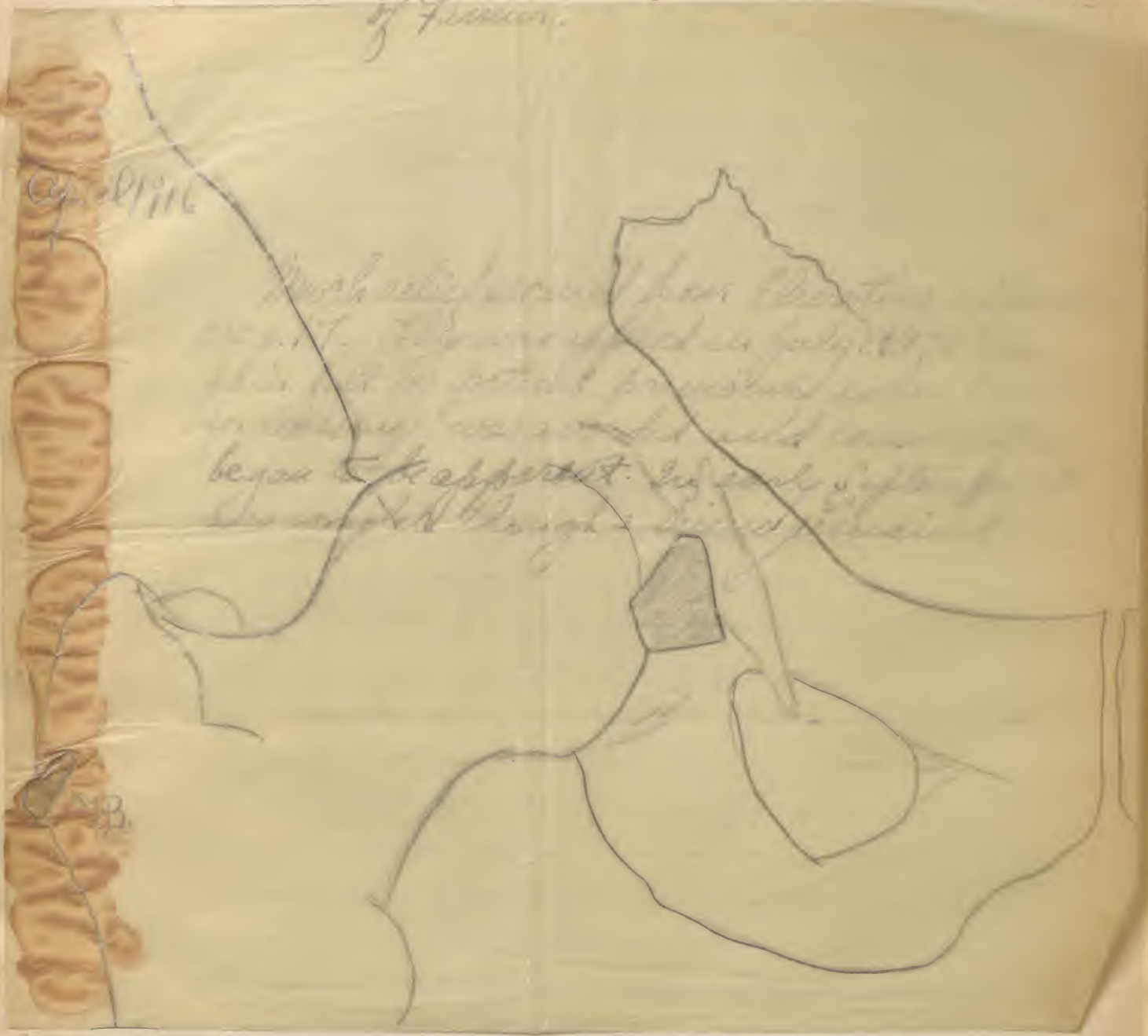

Wound - March 2. 1916 - Adm. May 28.

Operations - 3/2/16 F.B. Extracted, 3/2/16. Reduction of head of femur followed by suspension - extension, 3/7/16 Apparatus given up, no adhesion, no consolidation, 1/17/17 Formation of new acetabulum followed by abduction in a plaster cast, 1/25/17 - Wd. infected, drains inserted, 5/5/17 Eclat removed L. arm

5/6/17 Plaster given up - very little consolidation 9/1/17 - cuettement + replacement in acetabulum followed by plaster in abduction + external rotation 9/5/17 cast removed - consolidation. Patient 12/1/18 F. ambulatory a little

Aug 6, 1917

1917

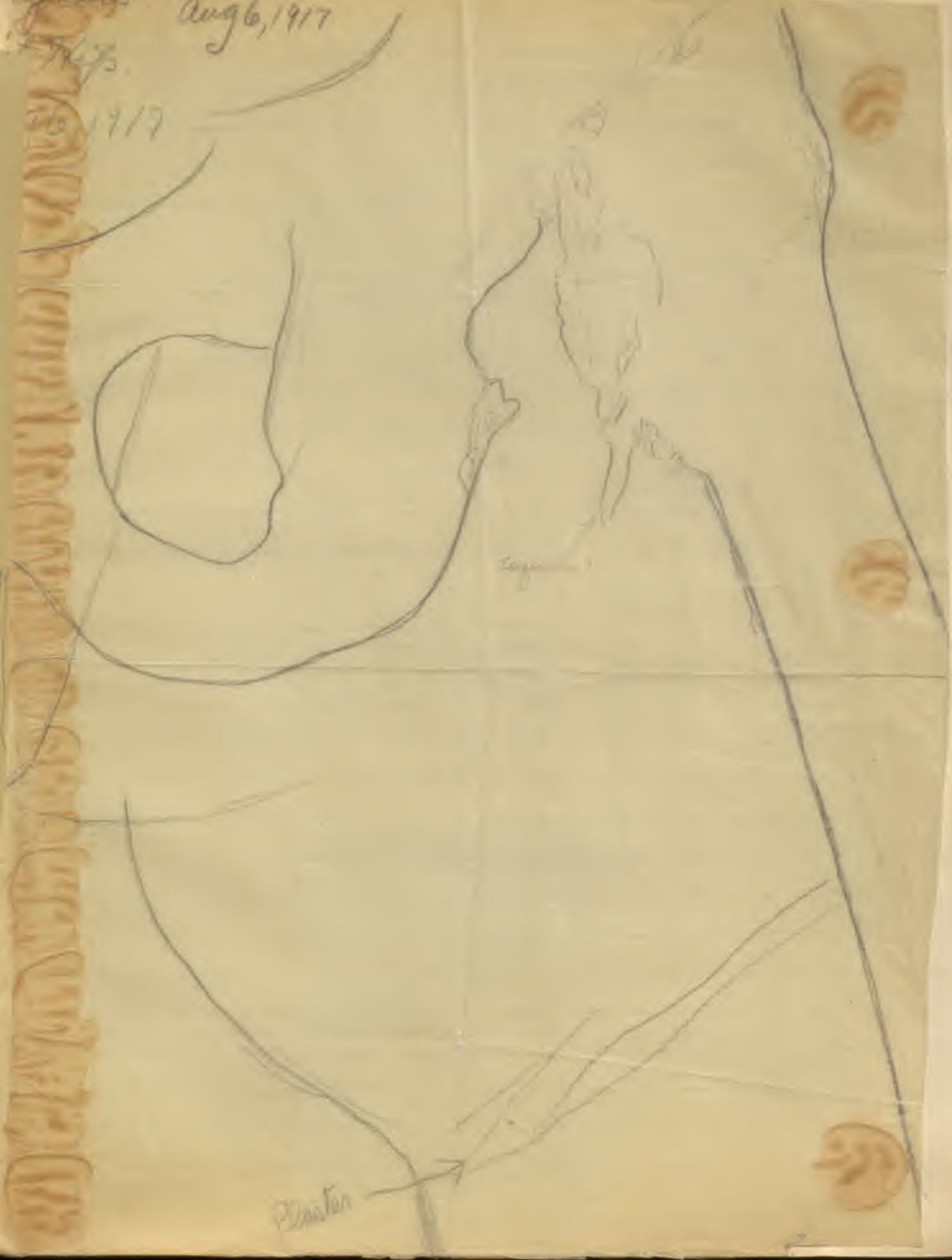

Langlois #90. - Fracture of L. innominate bone & head of Femur.

Much relief secured from Elevating apparatus see p. 17. This was applied in July, 1917. The pain felt by patient previously when turned for dressing was avoided and consolidation began to be apparent. In early September it was complete though a limp remained.

Present - March 2. 1916 - Adm. May 28.

Operations - 7/2/16 F.B. Extracted, 9/2/16. Reduction of head of femur followed by suspension - extension, 9/7/16. Apparatus given up, no improvement, no consolidation, 1/17/17 Formation of new acetabulum followed by Abduction in a plaster cast, 1/25/17 - Wd. infected, drains inserted, 5/5/17 Eclat removed L. arm

5/6/17 Plaster given up - very little consolidation 9/1/17 - curettement + replacement in acetabulum followed by plaster in abduction + external rotation 9/7/17 cast removed - consolidation. Status 10/1/17 Pt. ambulatory little

Aug 6, 1917

1917

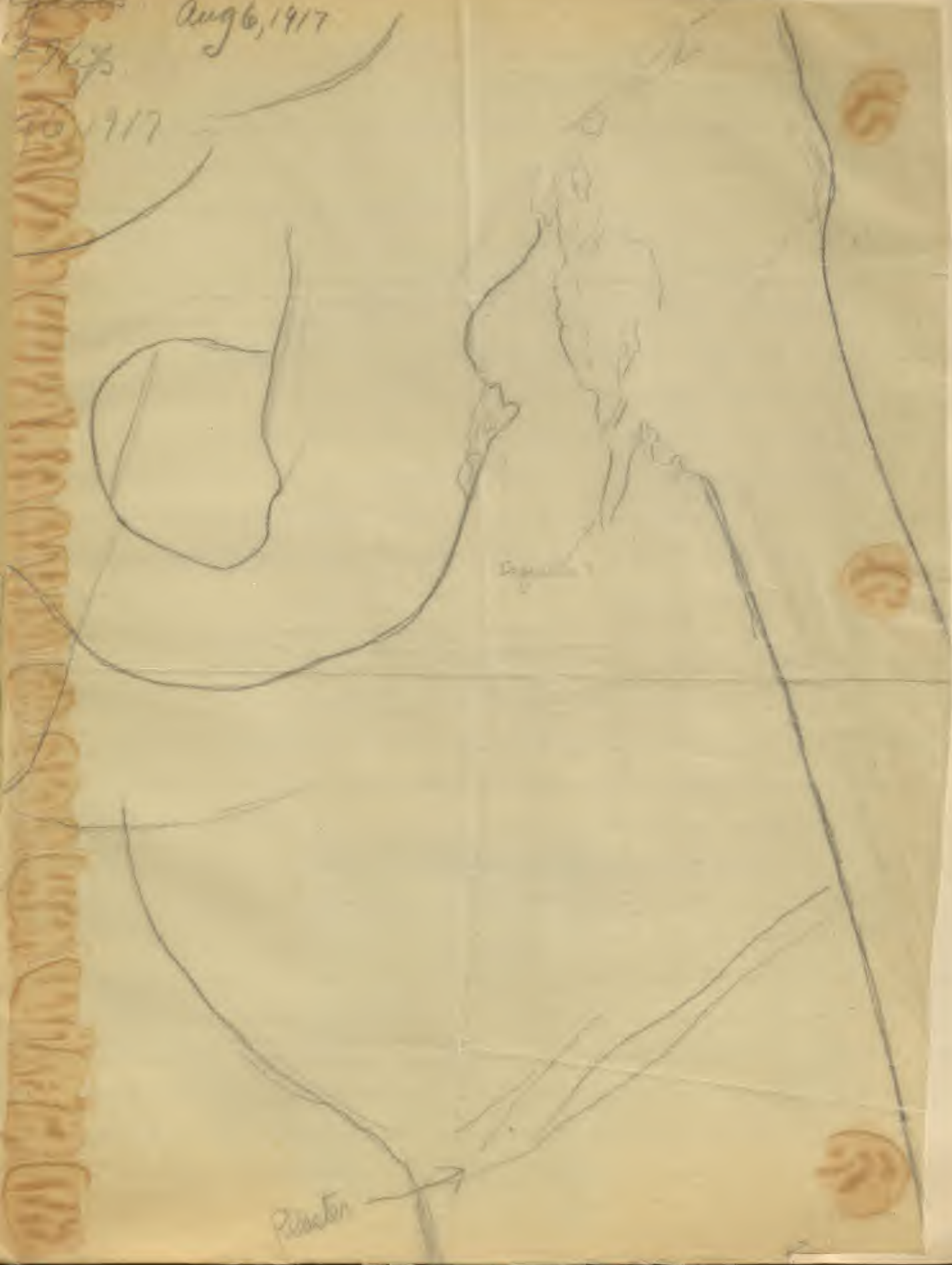


Aug 27.
Aug 29 1917

Tufferey. P.II.

Admitted Aug 20, 1917, Wounded Aug. 20, 1917

Diagnosis. - Irregular transverse fracture of lower ⅓ of L. radius + ulna. Seton wound

Treatment. - Cotton glove glued to hand. Forearm suspended perpendicularly ~~from~~ by strings run through rings in the glove & finger ends. Wound irrigated with Acetic + quinine per ~~Dakin~~ Carrel tubes.

Aug 3. - Haemorrhage of radial + ligature of same. Same date following operation forearm extended as follows - (see picture below. - Glove used to extend arm by means of rope over pulley at foot of bed. Counter extension by means of extension strips glued to ant. + post. aspect of forearm.

Consolidation

Arm taken down. Function of hand good though slightly stiff. Patient used to bend fingers of extended hand with other hand. Hence no real stiffness.

Discharged.

See next page for result.

See diagram p. 10.


Sept. 26, 1917
Jeffrey
Russell.

Sept. 20, 1111.
Jeffrey.
Pamlet.

Fig. 9. — Abduction extrême et rotation externe, dans un cas de fracture du col chirurgical de l'humérus. Le cadre fixé à la tête du lit a dû subir quelques modifications pour le traitement de cette fracture spéciale. (Se reporter au texte « Humérus », tiers supérieur.)

rale (fig. 5). Dans bras il est bon de

un mont une pou

du cubitus, muni des bandes des-
as blessé. La traction peut être
soit par un gant collé. La contre-
nnequin également représentée sur

tions, la
ment où
En effet,
e en un
bilisation
vlose la

de suspendre l'ava
tion verticale, soit
soit à l'aide de ban

Aussitôt que l'é
le permet, presque

Fractured Femur - Dill No 236.

236 Date Aug. 23, 1917

Steinm
Femur ac
frame on th
had prevo
the position o

Abduction a
extension in
way secure
the result se
on the ac
calcs.

2-36
Oct. 20, 1917
Result

Fractured Femur - D III No 236.

Steinman Pin passed through condyles of Femur and extension made by a small frame on this pin. Ordinary Strap extension had previously proved insufficient to correct the position of the fragments.

Abduction and extension in this way secured the result seen on the accompanying calcs.

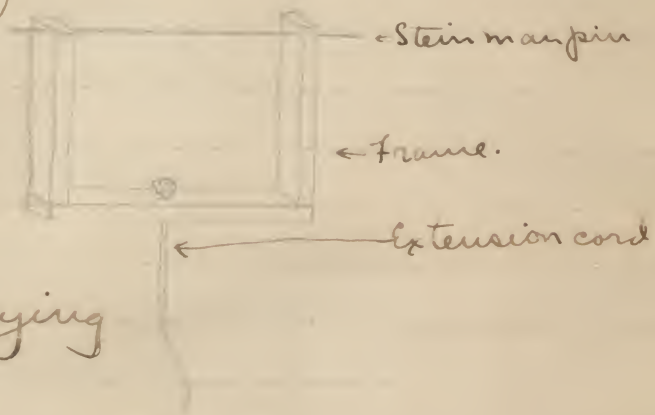

~~Abduction and extension femur in Thomas Splint.~~

Fractured Femur - Roger Dat. No. 163.

163. June 20

Roger.

Wounded May 23.

Suspended in Office, 23 with 14 lbs extension and [illegible]

Aug 27. Convalescing [illegible] and [illegible]

Broken [illegible]

Now [illegible] alignment [illegible]

Specimen

Femur showing for [illegible] after one & [illegible] non-fracture femur.

See results [illegible]

Roger 163 June 27

Roger

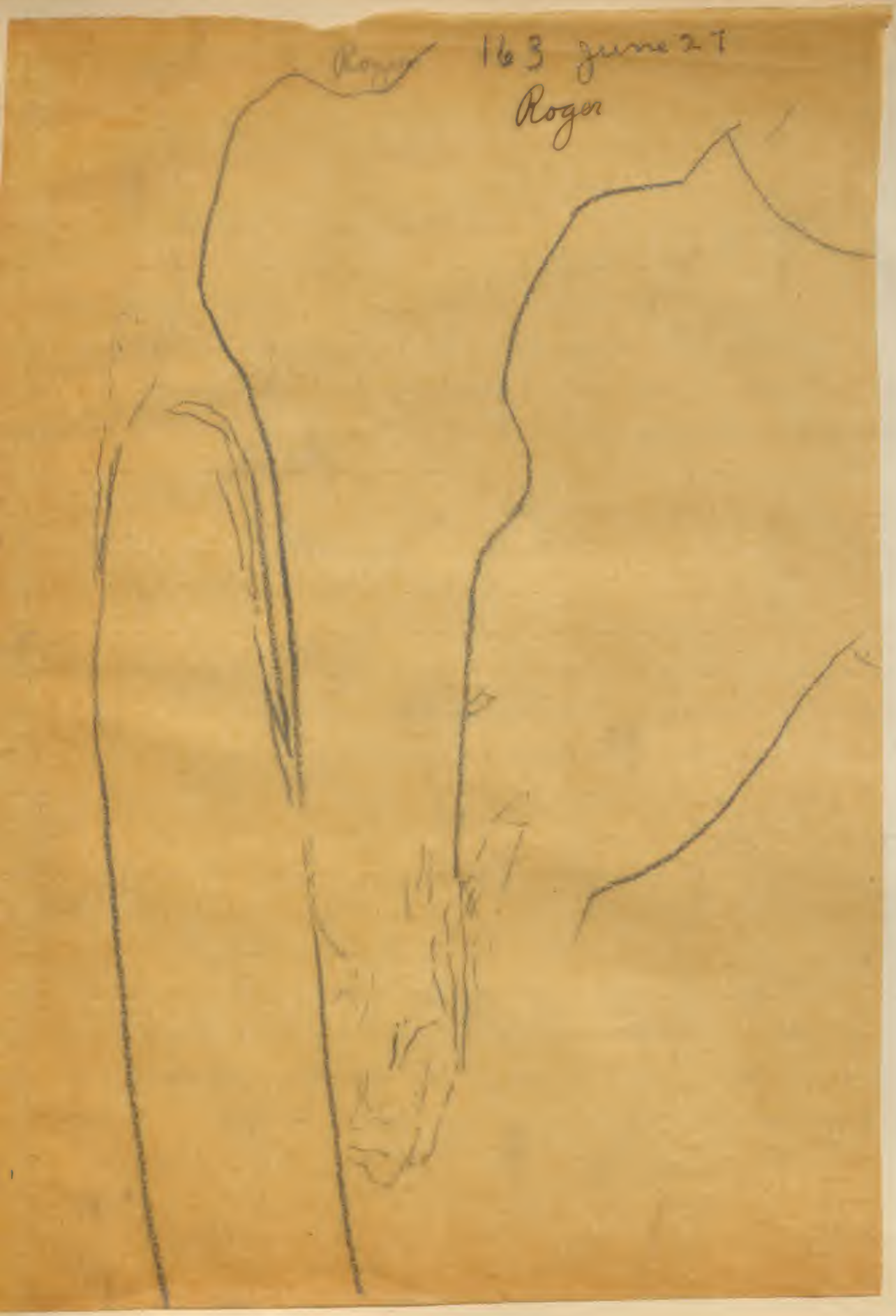

Fractured Femur - Roger D Pt No 163.
Wounded May 23.
Suspended as below June 20. with 14 lbs. extension and considerable abduction
Aug 27. Esquilectomy performed and union broken.
Nov. 3 Patient was walking with good ~~function~~ alignment of thigh and some stiffness at knee joint.

Abduction - Blake (Thomas) Splint.
Extension c̄ 7 pounds.

Frame providing for extreme abduction - Fracture Femur.



For further calcs see
pp. 41 etc.

Laboratories - Dr. Taylor - American Red Cross, 6 Rue Piccini

Routine for Swabs from Wounds.

1. Swab taken with heavy wire ~~cond~~ wound c̄ cotton from surface or sinus of wd. & place in tube plugged c̄ cotton.
2. Direct smears made - gram.
3. Agar slant made + swab placed in broth tube - Both incubated ½ hr. at 37°.
4. At same time as 3 above. Boil 1 tube of milk and one of meat ~~to~~ for ½ hour to drive out the ~~gas~~ air. - At end of time cool suddenly to prevent air entrance.
5. Transfer swab to meat carefully.
6. Transfer swab to milk + Incubate all four tubes 24 hours.
7. Examine milk tubes. Report stormy reaction to ward as B.A.C.
8. Incubate for 24 hours longer.
9. Make smears c̄ platinum ring (1) Bouillon (2) Meat (3) Slant (as many as seems necessary for various colonies on slant. (2) + (3) on one slide making circles c̄ blue pencil + passing from one to another without raising lens fr. slide.)

   $\boxed{\text{Ø}000}$ (4) milk - (all smears made from 5 different milks on one slide.)

   Stain c̄ gram.

For further calcs see pp. 41 etc.

n - American Red Cross, 6 Rue Piccini

coound c̄ cotton from
ygged c cotton.

d in broth tube - Both

milk and one of meat to for
end of time cool suddenly to

all four tubes 24 hours.

g reaction to word as B.A.C.

llon (2) Meat (3) Slabt (as many as seems
(2)+(3) on one slide making circles
without raising lens fr. slide.)
from 5 different milks on one slide.)

Sample Report on Routine Swab.

I. Book for data of swabs.

408 (~~serial~~ no.) (no of swab) 1126 (~~no of swab~~) (no. placed on tubes in culturing urines etc in series. Each time swab comes fr. same case a new no. is given)

27/10/17 Bigeon 469 (serial no)

Swab: Blood, Pus – Rt. Wrist

Smear: Serous, few cells, Bacteria.

B. (bouillon) Cocci, g-b (bacilli), g- rods spore bearing

Meat [gas] small oval g-b, g-b, g+ rods

Milk B.A.C. reaction – smear > Bac.

Sl. Staphylo albus + aureus (tell by looks of sl. and microscope)

II. Permanent Record Book.

Date - Rotolon No. - Serial No. - Floor - Ward - Bed - Name - Specimen for - Diagnosis - Results + Remarks.

27/10/17 1126 - 469 - P. - 28 - 3 - Bigeon Swab - Rt. wrist -

Aerobes: Staph, ~~g-bac~~ g-spore bearing bac sporebearer

Anaerobes: B.A.C.

~~g-bac sporebearer~~ other bac.

Culture Media.

1. Meat – Lean beef - grind it, mash in mortar, weigh + add equal wgt. of H_2O - place in tubes, add ⅓ as much again of peptone water (water, peptone + salt) Autoclave ½ hour. Before tubing make just alkaline to Ph.th. ē normal NaOH. B.A.C. reaction gives – Bubbles, pink color + odor of rancid butter.
2. Milk – (with the cream) tubed + sterilized in autoclave
3. Slant – agar slant. melt up some blood agar + pour over ordinary agar slant. 2½ agar. + 2% peptone
7. Boudlon.

For the Isolation of Anaerobes.

Get anaerobes on loop from meat culture

(Veillon agar used - Pasteur Institute - formula

1 % peptone
0.8 % gelose (agar.
0.5 % glucose
0.1 % KNO_2.

} percentage of the total volume made

Heat 3 agar tubes till melted. With platinum loop ~~loop~~ pass from first to second to third tube. Incubate. Choose a tube ~~to~~ where colony may be isolated, cut around tube c̄ a file. Apply hot bit of glass to cut, thus cracking & allow the agar to fall into a sterile petri dish. Pass Pasteur pipette draw isolated colony into it & withdraw & inoculate anaerobic meat & milk & examine.

B.A.C. reaction - Bubbles in meat. & Stormy reaction in milk. At the end of 24 hours the stormy reaction may appear. If so report B.A.C. to ward. Waiting 48 hours often brings out one not appearing in 24 hours.

4

2

B

M

M

St

L

Da

27/12/

O.M

2. N

3. J

4. K

47

Raymond-307- Fracture of Head of Humerus

307 Admission

Raymond

307 Post Admission

307 Date?

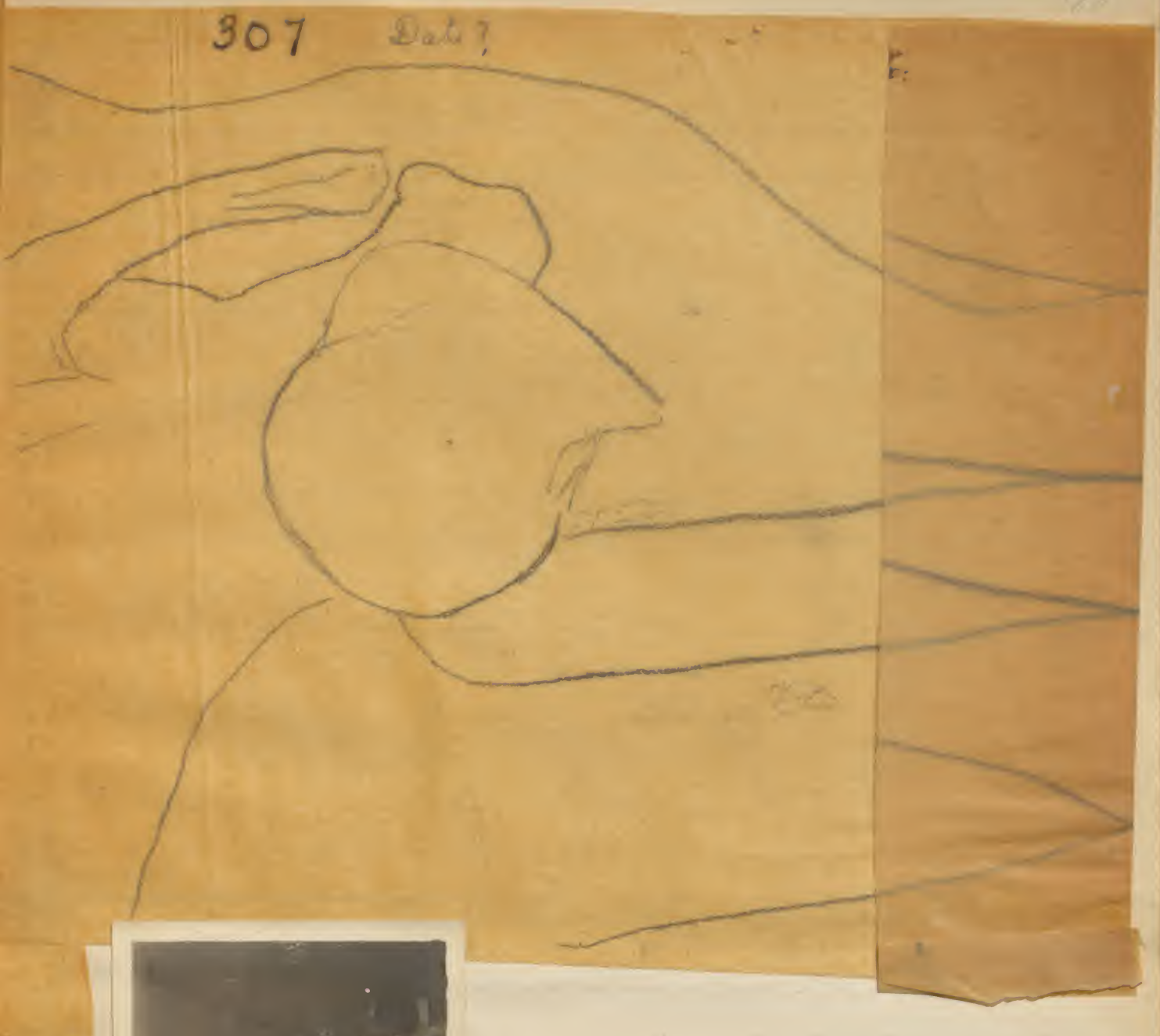

Raymond-357- Fracture of Head of Humerus

Wounded Aug 25.
Put up in Apparatus Sept 11.
Arm taken down about Oct 25. consolidated
See Selcs pp. 48, 49, 50, 51, 52.

307 Sept 18

307

307 Raymond
Sept. 8, 1911

307 Oct 23, 1917
Raymond. End Pencil.

58

Peter Bent Brigham Hospital # 1918-1919

Cystoscopy

Brown-Buerger cystoscope - Wappler Electric Co. Inc. - New York.
Sterilized in tin box provided c̄ a lamp to distill off fumes from formaldehyde tablet.
Irrigation and distension of bladder with 2 o/o Boric.
Lubricant - clear glycerine.
Anaesthetic - Cocaine 5 o/o - Female - administered c̄ toothpick swab.
(Alypin preferably) Male " " syringe. + milked back.
Patient in lithotomy position.

Pyelography. - Catheters in place - pt. to ~~operating~~ X ray room. Thorium Nitrate 15 o/o (25 o/o Na Bromide) caused to run in from burrette - ad pain (8-12 cc) Small tip on burrette tube corrugated + fine point. To x ray bladder 10 o/o Thorium nitrate.
If desired to fill hydronephotic cavity - use hand syringe at second X ray.

After Catheterizing ureters - get specimens for reduction. Then do a Phenol Sulphalein - 1 cc. intravenously. Note time of appearance of color (NaOH in tubes) Run 15' after color appears in first. Drink much water.



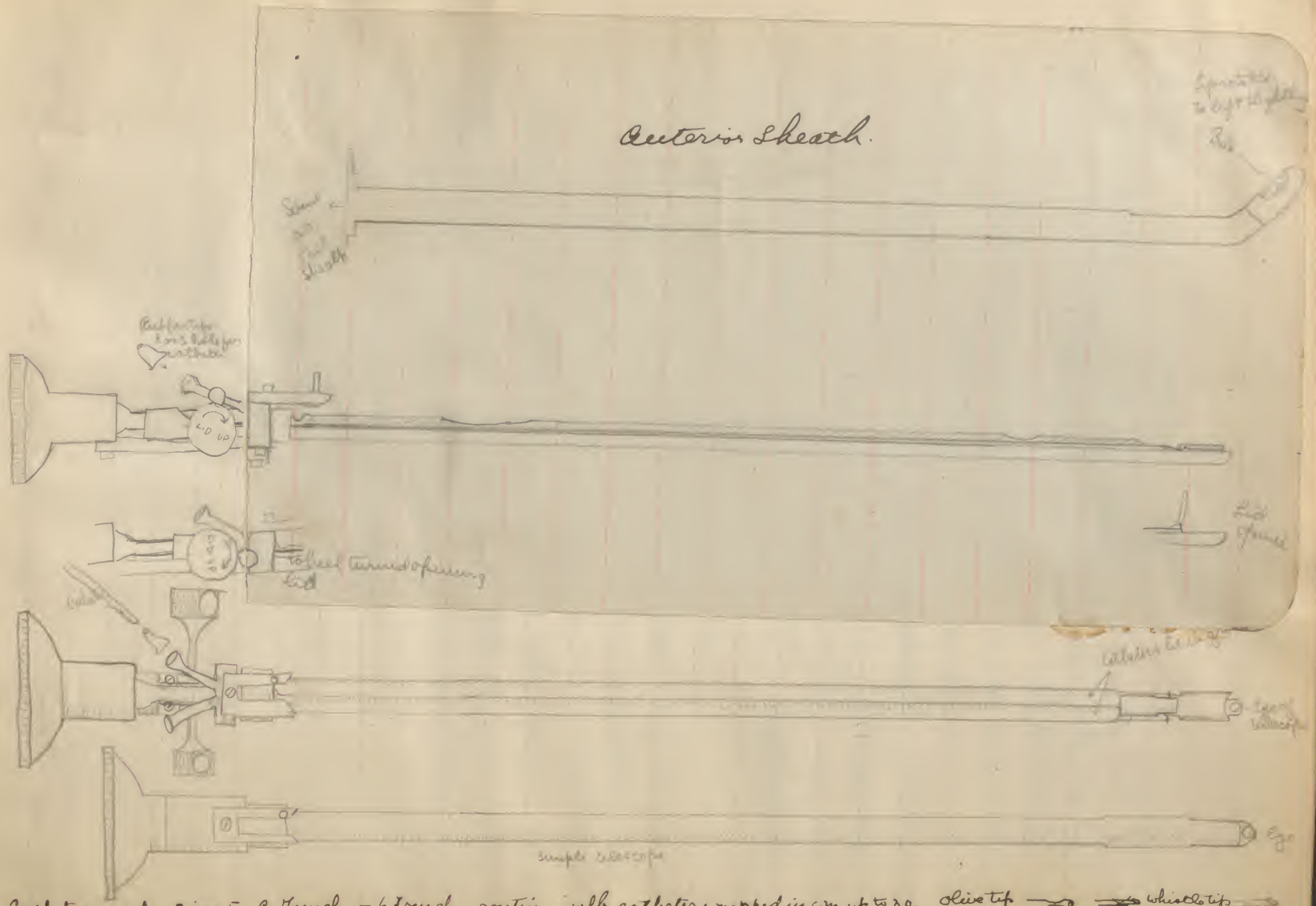

Catheters used size 5 - 9 French. - 6 French. - routine - wlb. catheters marked in cm. up to 30. olive tip ⟶ ⟶ whistle tip ⟶

New York

m + moved

a g filled

start

6 letters

more

end

ther. Start

or gauge

e. - 12 !

covered & duck

no

thetize

ed increase

m.

tc.



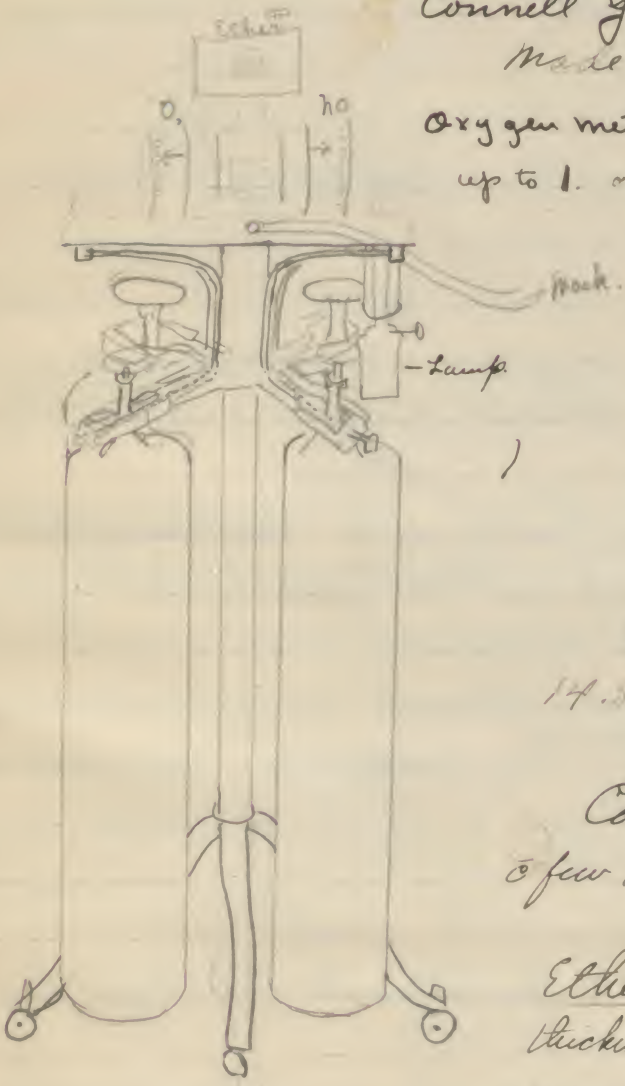

Connell Gas + Oxygen Machine

Made by Scientific Apparatus Co. - New York

Oxygen meter started at .8 Liters per min + moved up to 1. or 1.4 (or higher)

NO meter started at 6. (Bag filled w̄ any O_2 after breath or two start O_2.) Increase of NO above 6 meters not supposed to deliver any more gas.

Nasal tubes w̄ safety pin in end 14.5 cm. in length.

Cases having had previous ether. Start w̄ few drops of essence of bitter orange

Ether cone.  wire cone - 12? thicknesses of gauze over it and whole covered w̄ duck cover w̄ small hole 2-3 cm in diameter.

Connell Ether Machine -

Gives ether w̄ air at varying pressures. Anaesthetize well. Start machine at 76 mm. Hg. pr. of ether and increase to 90 rapidly. Then down - running at 30 - 45 mm. Catheter used for nasal tube. - Used for goitre cases etc. Mark on catheter 14.5 cm.

Spinal Anaesthesia.

~~Cocaine~~ Novocaine Gm. 0.150 dissolve in 3 cc. water in test tube. Boil down to 2 cc. Then inject in 4th L interspace, draw out cer. sp. fluid + reinject. Tip man head down to carry cocaine up. Duration 1½ hr. to 2 hr. Leg amputated perfectly.

G. U. Dept. O.D.D. - Wm C. Grimby.

Routine Solutions.

1-5000 $AgNO_3$, 1-1000 $AgNO_3$ - Sterile H_2O → Varying strengths
1-1000 Pot. Permanganate - Bladder irrigation.
2 Liter Bottles 1 o/o Sol. of Lysol - disinfect cystoscopes.
Formaldehyde 1 - Alcohol 250 (70 o/o) ℞ - cleaning up patient.
Carbolic Acid 2.5 o/o ℞ formerly used for cystoscopes (Instill 2 cc. into Post. urethra.
Boric Acid 2 o/o - irrigation c̄ cystoscope.

$AgNO_3$ 1 o/o } Pelvic wash. pyelitis
$AgNO_3$ 10 o/o } - Not to be used except in extremis
1 o/o usual.
$AgNO_3$ 4 o/o, 5 o/o - pelvic wash
Na OH. 10 o/o - reaction in Phenol Phth. test.
~~Boric 3. Water 500~~ ?.
~~HNO_3 conc~~. ?
Alcohol 70 o/o + denatured alcohol lamp under formalin sterilizer.
~~Neutral Formalin + Zeuker~~ ?
~~Acetic Acid Glacial~~ ?
Argyrol 10 o/o ℞ 25 o/o urethra, Bladder washes.
Protargol .5 o/o - female urethra in gonorrhea, also male.
Indigo Carmine 0.5, Nacl 0.6, water 100, Chromo urethroscopy. 1½ i.v. wait 15 min
~~Sol. Hyposulphite 1.7, water 100~~
Tincture Iodine. - Paint Cervix + Vagina - gonorrhea
Copper Sulphate 25 o/o - chancroid cauterization - reference G. U. diseases A.M.A. 1917 p. 17.
Formalin pastiles. - ℞ vaporized to sterilize the web catheters. Or bichloride may be used ~~for urethral catheters~~.

Iod-form 1gm. Guaicol 5 gm. Olive oil 100. – soothing + antiseptic for bladders.

Zn-Sulphate gm 0.2, Liq. Pb. Subacetate dil 100 ℞ = Astringent Inj. for dup urethra

Corrosive Sublimate 1-10 (40 cc dil to 500 = 1-1000)

Ichthyol 10% in glycerine – "tampon in Gon. + salpingitis

Sterile flasks Cocaine 5% – 2-3 cc. ♂ + ♀ urethra cystoscopy

" " Glycerine lubrication "

" " Petrolatum " instrumentation

~~H_2O_2~~ ?

Soda Bicarb, Soda Borate ãã ʒi, water ℥VI – swab mucous off os cervix dissolves mucous.

℞ Litmus paper.

Muko (tubes) L. F. Chapin Co. Boston Mass. – Lubricant to glove fingers + sounds + catheters.

Table (men's room. (1) Bowl – Bichloride (1-1000) c̄ tips to urethral syringe + Kollman "McCleary piston" "McCleary Safety Trump" covers. – (2) Metal urethral syringe. (3) glass plunger syringe for cocaine in male urethra etc. (4) Bulb urethral syringe (5) powdered gloves, (6) muko. (7) medicine flasks. (8) Sponge sticks in alcohol. (9) dry sponges (10) Alc. sponges. (11) Tooth picks Swab and spatulas, (12) cotton fluffs, (13) scissors (14) flasks – cocaine 5%, glycerine +, petrolatum, (15) 500 cc flask for bladder wash fluid. (16) Kollman. (17) Basins (18) urine ~~flasks~~ glasses.

Also. – towels + hole towels.

Sterilization. Catheters in formalin vapor box as bougies Sounds – boiled.

Cystoscopes – cleaned c̄ soap + water. Placed in 1% Lysol before using + transferred to sterile H_2O. (In house, sterilized c̄ formalin vapor)

Ureteral catheters – in formalin or bichloride (1-1000)

Cystoscopes – All Brown – Berger made by Wappler Co. i.e. Ant. – Post. sheath + urethroscopes. An operating scope fits either ant. or pos. sheath. Brush Scope

allright for direct vision.

Followers (for filiforms) cleaned in soap + water + wiped c̄ alcohol sponge before use. Filiforms sterilized same as catheters etc.

Lights for cystoscope - 4 ever ready batteries in a wooden box. Or a step down on direct current.

Kollman covers boiled each time.

Diarsenol Arsphenamine. - P.B.B. Urological O.P.D.

Apparatus. (1) Glass stoppered bottle - graduated in 25 cc. c̄ fils. Sterilize with stopper off + wrapped in gauze. (2) Long solid glass stirring rod for breaking up a last fragment of arsphenamine if necessary. (3) 1 cc (or 5 cc) pipette for dropping in NaOH. (4) Long high pressure rubber tubing with a three way stop cock. (5) Rubber stopper with glass tubes attached to fit bottle. (6) Wassermann needle to fit connector on tube. (7) Sterile salt solution, normal at blood temp. ~~distilled~~ twice distilled over glass. (8) NaOH. Chemically pure. 15 o/o (or 20 o/o) Diarsenol Arsphenamine made by _____

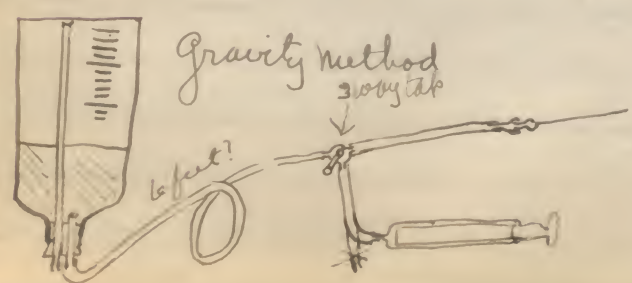



Procedure.

Dosage – first time 0.2 gm. or 0.4 gm. according to size. Next time boost to 0.6 gm. F.

I ck dearsenol ampoule & breakoff top. – Powder in bottle (1) Add at least 25 cc. saline (7) for each 1/10 gm. dearsenol. (Do not have it too hot nor too cold) Stopper with glass stopper and shake till dissolved. Add drop by drop the NaOH (8) until clear (neutral) Make up enough for the days treatment at one time or just ~~a~~ run out from bottle the dosage desired.

Patient recumbent, clean up arm c̄ sterile towel under. Lobe c̄ tubing syringe etc are sterile. Scrub up. Insert needle in tubing holder & insert in vein with 3 way tap connecting syringe with needle and saline in syringe. Determine that you are in vein by drawing on syringe & reinjecting ~~without~~ without producing hematoma. Then, in gravity method allow dearsenol to flow in. Or by syringe method draw out by turning tap + inject c̄ syringe.

Tuberculin. Dosage.

allright for direct vision.

Followers (for filiforms) cleaned in soap + water + wiped c̄ alcohol sponge before use. Filiforms sterilized same as catheters etc.

Lights for cystoscope - 4 ever ready batteries in a wooden box. Or a step down on direct current.

Kollman covers boiled each time.

Diarsenol Arsphenamine. - P.B.B. Urological O.P.D.

Apparatus. (1) Glass stoppered bottle - graduated in 25 cc. c̄ file. Sterilize with stopper off + wrapped in gauze. (2) Long solid glass stirring rod for breaking up a last fragment of arsphenamine if necessary. (3) 1 cc (or 5 cc) pipette for dropping in NaOH. (4) Long high pressure rubber tubing with a three way stop cock. (5) Rubber stopper with glass tubes attached to fit bottle. (6) Wassermann needle to fit connector on tube. (7) Sterile salt solution, normal at blood temp. ~~distilled~~ twice distilled over glass. (8) NaOH. Chemically pure. 15 o/o (or 20 o/o) Diarsenol Arsphenamine made by _____

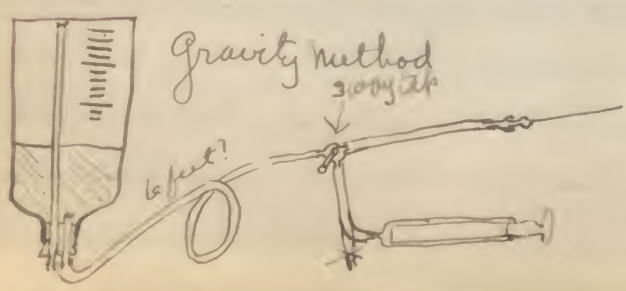



Procedure.

Dosage – first time 0.2 gm. or 0.4 gm. according to size. Next time boost to 0.6 gm. F.

Fill Kearsenol ampoule & breakoff top. – Powder in bottle (T.) Add at least 25 cc. saline (T.) for each 1/10 gm. Kearsenol. (Do not have it too hot nor too cold) Stopper with glass stopper and shake till dissolved. Add drop by drop the NaOH (S.) until clear (neutral) Make up enough for the days treatment at one time not just to run out from bottle the dosage desired.

Patient recumbent, clean up arm c̄ sterile towel under. Lube c̄ tubing syringe etc are sterile. Scrub up. Insert needle in tubing holder & insert in vein with 3 way tap connecting syringe with needle and saline in syringe. Determine that you are in vein by drawing on syringe & reinjecting ~~without~~ without producing hematoma. Then, in gravity method allow Kearsenol to flow in. Or by syringe method draw out by turning tap + inject c̄ syringe.

Tuberculin Dosage.

DOSAGE OF OLD TUBERCULIN		METHOD OF INCREASE.
#6 – 0.1 cc of #5 plus 0.9 cc of H_2O	0.1 cc = 0.0000001 cc. O.T.	1 – 0.1 cc 2 – 0.1 cc 3 – 0.2 cc 4 – 0.2 cc
#5 – 0.1 cc of #4 " 0.9 cc of "	0.1 cc = 0.000001 cc. O.T.	5 – 0.1 cc 6 – 0.2 cc 7 – 0.2 cc 8 – 0.5 cc 9 – 0.5 cc
#4 – 0.1 cc of #3 " 0.9 cc of "	0.1 cc = 0.00001 cc. O.T.	10 – 0.1 cc 11 – 0.2 cc 12 – 0.2 cc 13 – 0.5 cc 14 – 0.5 cc
#3 – 0.1 cc of #2 " 0.9 cc of "	0.1 cc = 0.0001 cc. O.T.	15 – 0.1 cc 16 – 0.2 cc 17 – 0.5 cc 18 – 0.5 cc
#2 – 0.1 cc of #1 " 0.9 cc of "	0.1 cc = 0.001 cc. O.T.	19 – 0.1 cc 20 – 0.2 cc 21 – 0.5 cc 22 – 0.5 cc
#1 – 0.1 cc of O.T. " 0.9 cc of "	0.1 cc = 0.01 cc. O.T.	23 – 0.1 cc 24 – 0.2 cc 25 – 0.5 cc 26 – 0.5 cc

TREATMENT FOR BICHLORIDE POISONING.
(As worked out at St. Luke's Hospital, New York.)

1- Copious stomach lavage with water or induced copious vomiting. After washing out stomach leave 250 c.c. of milk and 100 c.c. of 50% albumen water (white of egg).

2- Stomach wash every 3 hours first day same as no. 1. Afterwards twice daily until urine is free from mercury.

3- Every alternate hour give 8 oz. of alkaline solution, viz., potassium bitartrate
sugar ana ℥i
lactose
lemon juice ana ℥i
boiled water ad ℥ XVI

4-Every alternate hour 8 oz. of milk.

5-Murphy drip of the following solution: potassium acetate, one drachm to 1 pint of water.

6-High colon irrigation twice daily.

7-Daily sweat in hot pack or by other means.

Urine is secreted from abbve treatment in large amount. Treatment is to be continued until urine shows negative tests for mercury on 2 successive days.

Instruction for Acute Urethritis Cases.

Cleanliness.

Wash the end of the penis at least twice a day with warm water and soap, retracting foreskin, etc.
Immersion of penis in glass of hot water t.i.d. is good.
Urination with penis immersed in hot water is advised.
Care to clean hands after urination, injection or handling.
Do not use common bath tube.
Care not to leave discharge on toilet seat.

Discharge.

Gauze bandage about penis held in place by foreskin if present.
Gauze bag if no foreskin.

Rest.

Get as much sleep as possible. Reduce physical exercises. Riding instead of walking. No dancing, bowling or exertive sports. Sexual rest. Absolutely no intercourse. Prevent erections if occurring, (cold bath before retiring or KaBr. gr. 30).
Suspensory or Jock strap in the acute stage.

Food.

Absolutely no alcohol or soda fountain drinks.
Spices are forbidden.
Coffee and tea in moderation.
Increased flow by drinking much water in acute cases.
Moderate water intake in posterior cases as frequency of urination may cause urethral irritation to persist.

Bowels.

At least one movement a day is necessary.

Internal medication -

Rx. "Compound Salol"

Salol	gr. iiiss	or	.2 gm.
Copaiba	mins. X		1. cc.
Oleoresin cubeb.	" V		.5 cc.
Pepsin (1-3000)	gr. 1		.06

Mix and make capsules.
Sig. One after each meal t.i.d. with full glass of water.

or

Rx.

Salol	gr. IV	.2
Oleoresin sant.	min. V	.5
" cubeb.	" V	.5
Olive oil	" V	.5
Pepsin (1-3000)	gr. 1	.06

Adminster same as above.

or

Ol. Santali gm. 0.5 T.I.D. P.C.
Capsules.

1

Ur

ti

sandalwood oil or Wintergreen oil mins. 10 as above. If the above upset the stomach.

Urozan in 10 min. capsules t.i.d.
Give the above (unless distressing) from the time the patient comes until the urine is clear of pus (not shreds).

For irritability at bladder neck and dysuria -

Liquor potassae	8 to 25 gr.	.6
Fluc. hyoscyamus	15 to 35 gr.	.9
Aquae cinnamomi	q.s. ad. 100 gr.	6.

Teasp. in water q 3 hours.

give Hexamethylen amine gm. 0.3 T.I.D. P.C. in H_2O
with Acid Sodium Phosphate gm. 0.3 T.I.D. P.C. " if urine alk.
if there are signs of bladder infection.

men.- Gonorrhea.

Cervix if indicated with 10% $AgNO_3$ on swabs
tincture of iodine. Vagina with tinct. of iodine
urethra with finger, if there is pus either swab or instil
protargol into urethra. Force fluids, rest etc.
glycerine ~~ous~~ or glycerine + ichthyol tampon + remove
hours.- Douche B.D. Pelvis Menthol Compositus.
quart of H_2O.

alcohol 70% 250
Formaldehyde 1 f
for hands + field.

Operations P. B. B. Hospital.

Bichloride for hands + field 1-5000

Appendicectomy.

Cleaning set method - for all operations. i Shave + wash in P.N. ii a towel above + below area over clothes. iii Alcohol sponges taken in bare hands 3 sets. iv. Bichloride 1-5000 sponges 2 sets. v. Lap sheet (oblong opening) vi. Towels fastened c̄ towel clips. vii Double sheet below + above + one over feet. (First ass't has previously scrubbed 5 min. then alcohol + Bichloride 1-5000 5 min.) Alc. + Bichloride again to hands, gloves in water, gown. (or gloves in Bichloride

Incision. (R. rectus) over middle of R. rectus ~~from~~ beginning a few cm below level of umbilicus, about 8 cm. in length, wall off the skin c̄ gauze ~~[illegible]~~ pinching pad + mayniken clamps rectus muscle reflected medially, take care to only push nerves up or down. Peritoneum with forceps first then knife. Kelleys on peritoneum. ~~follow~~ Appendix out of wound. #1 chromic cat gut to tie ~~vessels~~ in append. mesentery and mesentery cut. Appendix crushed at base ~~and~~ with Kelley clamp which is then moved up a little and clamped. Plain cat gut #1 about appendix in cecum line + ~~tied~~ Place + provisionally tie a silk purse string off with saline gauze wall off. tie to steady. Cautery between clamp and tie. Pair of Halstead (straight) clamps on base of appendix + ~~tie the cut. Stump~~ Cut tie. Invert stump c̄ Halstead + if necessary muc. memb. (Alice) clamps on caecum near. Tie purse string after inversion. Invert + tie another purse string or a mattress stitch to further invert. Mesentery over site. Close peritoneum with #1 double plain cat gut. continuous (Dr. Jacobson) or with #1 single continuous chromic (Dr. Cheever) Same stitch may be used to draw rectus back in place after closing peritoneum. #2 interrupted chromic cat gut for fascia. Mattress stitch. →



Side A is overlapped over side B. Stitch 1 is taken away from operator and 2 toward him.

Fat + fat fascia approximated by #0 plain cat gut. Skin incision by silk on ~~plain~~ straight needles

Bichloride sponge to skin, Silver foil over incision. gauze + adhesive strips.

Pyelotomy for Stone.

Iodine + Alcohol Prep. – Pt. on side c̄ sand bag under side and table tilted. Gas + Oxygen.

Flank incision – From just below 12th rib + out. to Lat. Dorsi downward + forward. Expose Ext. oblique + split fibres then cut across them in line of incision + retract. Cut internal oblique. Incise the capsule over renal fat. Case – peritoneum.

Split the fat + handle as little as possible. Manually shell out kidney. Take care not to strip off kidney capsule.

Deliver kidney. Incise pelvis posteriorly & scoop out stone c̄ gall bladder scoop. Sew up pelvis w. refined fat c̄ stitch. By denuding kidney of capsule a little it is apt to fix itself in position by adhesions. Leave saline hot in fossa. If more space is needed the costo vertebral fascia may be removed. Cut. Cut muscle closed in layers c̄ interrupted chromic sutures. Skin cat gut to fat and silk to skin.

Nephrectomy – Steps similar to above except that kidney pedicle is clamped c̄ right angled clamps. In difficulty use big kidney clamps

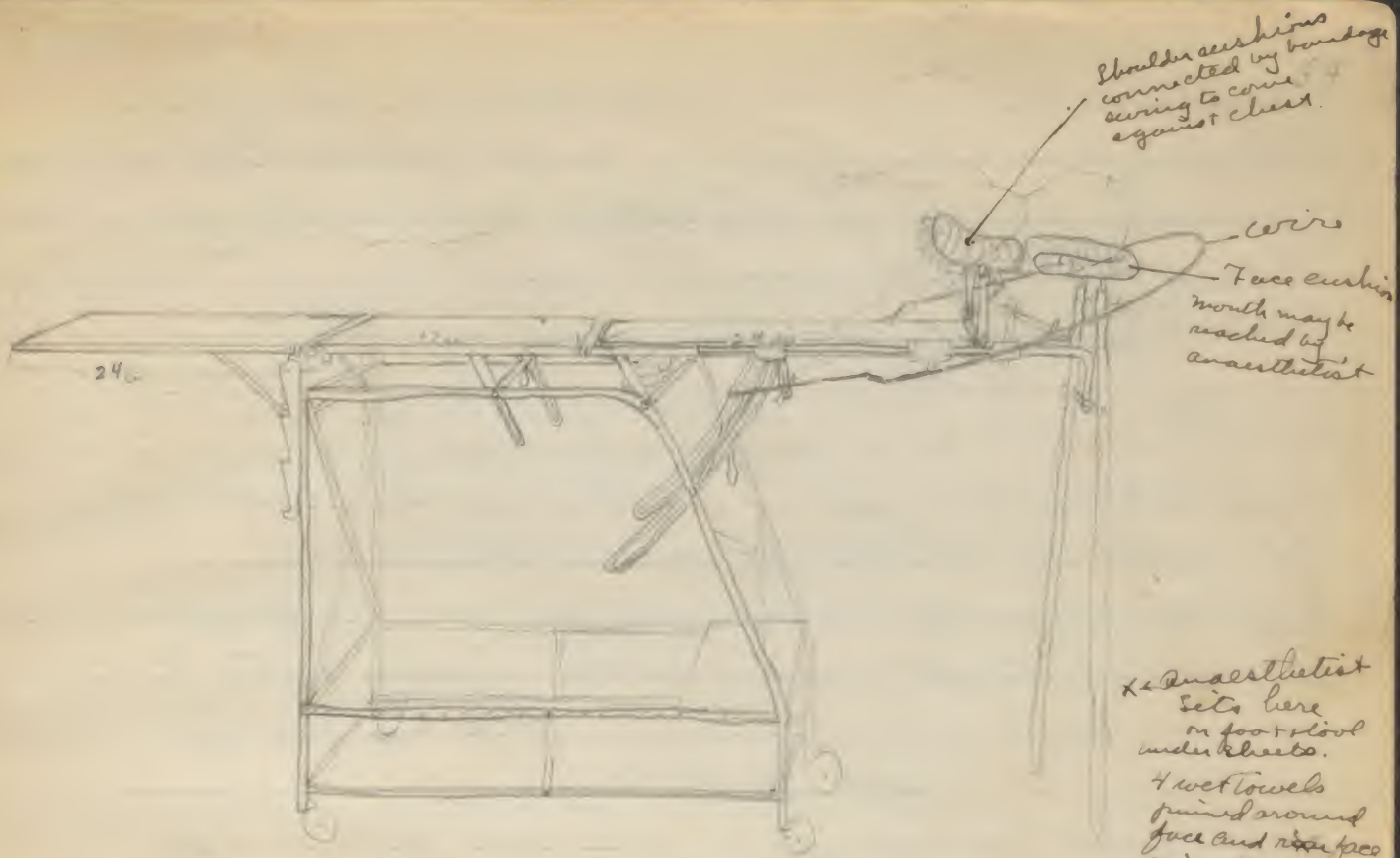

Cerebellar Operation.

Preparation. – Back of head shaved. By orderly.
Cushing – bichloride towel over hair. Alcohol sponges
to field. Incision out lined by knife
Bichloride sponges. One layer of 9 wet
gauze over field. Sheet pinned to head
so it falls over the wire above + covers anaesthetist.
Bichloride towels to shoulder. L. shaped table over shoulders
+ gray sheet over that and all of head except field
Incis out along lines of incision already out lined.
Incision deepened. ~~to~~ Swabs put on deep layers of scalp + turned out
to cause hemostasis. Swabs held in rows by a sponge ~~bar~~ folded
Above indicated incision deepened to skull + periosteum
& scraped back by periost ~~elevator~~ elevator

Instruments.

Scalpel (straight. ? _____ Snaps c̄ silver clips _____

Small cotton swabs pressed out in saline. Bone wax _____

Periosteal elevator, joker or spud. Rongeurs _____

Needle ? _____

Perp. cut must be just in mid line continuing down to Atlas as it has to be removed at times.

Bone Bleeding stopped c̄ bone wax put on c̄ finger & joker

Bone exposed down to canal. With electric motor and round bit  ~~two~~ one hole made on either side of occ. protuber. Enlarged by hand rasp + bit, beginning in holes bone bitten out by rongeurs of various shapes 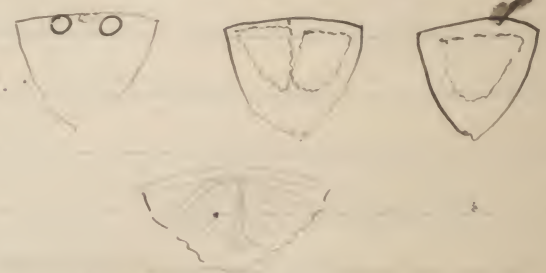

Large ~~bone~~ fixed bone clamps used also.

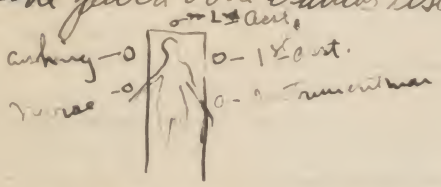

~~Exposure not large enough~~. new hole higher on the Left. Ventricle tapped via _____? by needle which is left in place. Dura lifted by tiny hook. Small hole c̄ scalpel. Groove director inserted + cut made on it. Dura reflected Spoon Spatula under dura + further cut made c̄ scissors Bleeders in dura stopped c̄ silver clips. L. lat. cerebellar lobe lifted c̄ spatula for inspection. Small cut in L. cerebellar lobe and a blunt trocher introduced into cerebellum. Small amt. of fluid from probable cyst. Too deep for removal.

Ganglion. Cushing (Hunt. Hosp.?)

3

Robert Rosenbloom. Surg. No. 10,036
13 yrs.

At 7-8 - severe frontal headaches.

18 months ago. blurring R. eye. followed by blindness here
1 yr. ago blurring of L. eye + Decompression in N.Y.
Int. strabismus of R. eye as long as he can remember.

Pos. Findings.

Subj. - complete loss vision in R. eye. Impairment of vision L.
L. hemianopsia.
Fundus O.D. optic atrophy - sl. edema discs?
R. Int. strabismus of R. eye.
Hearing sl. better on L. side.
Slightly under size. No dystrophia adiposa genitalis.

Op. Transfrontal approach to Pituitary.
Horse shoe incision above ~~L.~~ R. orbit.
Surrounding the chiasm + rather more to
right was a large tumor color of mother of
pearl & shelling out like wet saw-dust.
A cholesteoma, the second Cushing has seen.
When scooped out ē pituitary spoon one could
see chiasm and circle of Willis! Good
ether recovery.
Dr. Cushing had refused once to operate at a previous
admission.

Brain / Spatula

ou side. high table
l app. ether
Gauze had been
e at top. of incision
re shine - ec. + hand
+ can't tell
r 3cm. in diameter
rgeal is sought
ped ō bone wax
much use of ~~cotton~~
to wax. Rest
t ē a tiny wire
ing from ganglion
are exposed.
+ over the
)
ivotia forceps
D + IV.
, be evulsed:
moved.
lessen the floco
+ lessen the
ed as hemo-
before closure
muscle edges
s ~~sacked~~
edges
cavity filled ē
ed

Robert Rosenbloom.. Surg. No. 10,036
13 yrs.

At 7-8 - severe frontal headaches.

18 months ago. blurring R. eye. followed by blindness here
1 yr. ago blurring of L. eye + Decompression in N.Y.
Int. strabismus of R. eye as long as he can remember.

Pos. Findings.

Subj. - Complete loss vision in R. eye. Impairment of vision L.
L. hemianopsia.
Fundus O.D. optic atrophy - sl. edema discs?
R. Int. strabismus of R. eye.
Hearing sl. better on L. side.
Slightly under size. No dystrophia adiposa genitalis.

Op. Transfrontal approach to Pituitary.
Horseshoe incision above R. orbit.
Surrounding the chiasm + rather more to
right was a large tumor color of mother of
pearl & shelling out like wet saw-dust.
A cholesteoma, the second Cushing has seen.
When scooped out c̄ pituitary spoon one could
see chiasm and circle of Willis! Good
ether recovery.
Dr. Cushing had refused once to operate at a previous
admission.

5

Wm Dolan 35. Surg. No. 11,123

Hypophyseal

3 years ago blow on head - followed by severe headaches in attacks.

Partial strabismus of L. eye 8 yrs ago. + L. hemianopsia of L. eye - disappeared after glasses.

3 yrs. ago blow on head + development of epileptic seizures preceded by faintness also hot flashes + headaches.

No secondary sex characteristics till the past 3 yrs. during which time he has had pituitary extract. Pubic hair + hair on upper lip now. emission 1 month ago.

Findings.

Subjective. Headaches, epileptic attacks; hot flashes

Objective - Hypotrichosis - skin soft. Skeletal undergrowth, adiposity, aplasia genitalia

Perimeter normal. Metabolism -20. B.P. low.

~~Not Funiden~~

Op. Sept 14. Transphenoid. Base of sella removed.

Tumor did not extrude into opening. He feared bleeding + leakage too much to enter substance

Therefore closed, to remove the tumor from above another day.

Case. R. Glioma tous cyst Temporal Lobe.

Notes - Cs July 31.

Hx. 9 years ago lack of ambition 4 yrs. ago head aches L. ~~parietal~~ occipital. 2 months headache + vomiting occasional but ~~f~~ continual nausea. Unstable emotionally. Dis orientation. - Pt. brought from Portland Oregon not cooperative on arrival. + stuporous.

Pos. Findings.

Subjective. Headache - occipital, Vomiting, unsteady gait

Objective. Emotional instability. Dis orientation

Bilateral choke disc 4 - 5 D. Static + intention tremor L. hand. Cutaneous sensibility generally diminished.

Some suboccipital tenderness. + flexion of head on chest gives pain. Exaggeration of tendon reflexes L. side, Pos. Romberg.

Note from L.N.D. reported a L. homonymous hemian opsia

X Ray - indicated pressure in frontal region

Dr. Cushing planned to do a R. ~~bone flap~~ occipital lobe bone flap but after shaving head the veins on L. side of scalp were more dilated + after demarcating incision on R. he ~~transferred~~ to had an "inspiration" decided to doubt the above L. hemian opsia + did a R. subtemporal decompression.

1st Op. Sub temp. Decomp.

Widened convolutions. Needle in second temp. convol. to 6 cm. neg. in 3d convol. 5 cm + got ounce of straw colored fluid 60cc in alb. Carrel syringe + ~~of~~ asp. needle wet filled c 10% formalin for 5 min. Wd closed in layers.

Fluid Sp. Gr. 1.010, Alb. ++. Sugar 0. Sed. 0.

After op. - uncinate gyrus attacks + visual hallucinations recovering to op. described. - Onset. Quite deaf came not apparent after op. 3d R. nerve palsy.

2nd op. - Explor. ~~but~~ to see if cyst had been extirpated. It was not. Hence closure.

Case. R. Gilmerton cyst impacted left.

Ca - C3 pelv 31.

Pain one back of condition hips. one had colic
[illegible] crepitat. 2 months back colic + vomiting
[illegible] first of continued nausea. Inclosed inter-
[illegible] obstruction. - Pt. brought from Portland Orkney
[illegible] on arrival + stopped.
[illegible] dining.
[illegible] Head colic - crepitat, vomiting, waterbody pain
[illegible] . Constipation inadmissible. Also constipation
[illegible] colic c + 3 D. Stools + intestinal tumour.
[illegible] sensibility generally diminished.
[illegible] subcrepitat tenderness + fller in of head on clear
[illegible]. Exaggeration of tension. Affected side.
[illegible]

[illegible] M.B. reported a. of tumour among [illegible]
[illegible] with cystic [illegible] in [illegible]
[illegible] [illegible] left on [illegible]
[illegible] pleurisy to ob a. R. [illegible] left side observing
[illegible] in L. kidney. Occasionally [illegible]
[illegible] observations in urine on R. [illegible]
[illegible] "impaction" [illegible] to [illegible]
[illegible] tension of [illegible] + [illegible] R. [illegible]
[illegible]
[illegible] bad temp. [illegible]
[illegible] and convalescence. Needle in general temp [illegible]
[illegible]. in 3d general. 3 [illegible] + part [illegible] of [illegible]
[illegible] fluid 600 cc in left [illegible] cyst + [illegible] [illegible]
[illegible] 10 p [illegible] for 6 [illegible]. [illegible] [illegible]
[illegible] 1.010, [illegible] ++. Sugar 0. Sed 0.
[illegible] [illegible] [illegible] [illegible]
[illegible] [illegible] [illegible] [illegible]
[illegible] R. [illegible] [illegible]
[illegible] [illegible] [illegible] [illegible]
[illegible] [illegible] [illegible]

Case. ? serous arachnoiditis

Joseph Parasboschi June 2, 1919 c 2

2. 4 yrs. ago. Pain in back of neck. tt 1 yr. ago occipital
adache. 2 months vomiting 4 yrs. ago squint corrected by
lasses. 1 yr. R. internal strabismus. Loss of vision.
yrs. slow talking. 3 recent convulsions.
bjective: [illegible]ings - Drowsy - lethargic. Retarded speech
~~vis R. [illegible] Sl. on L.~~ Choked disc. pupils dilated
omberg. falls to L. Mod. Exophthalmus
facial paresis. L. hand falls when horizontally held.
KJ diminished. Romberg pos. to L. + back. Cracked pot.
esonance to head. Dil. veins of head. Head on L. side +
yperextended. Pass pointing to L. ā both hands.

(1) Op. R. Subtemp. Decompression. Puncture of Lat. ventricles
In view of complete absence of incoordination or of nystagmus
felt not justified in exploring over cerebellum.
thing found. much fluid withdrawn.

(2) Op.
ly 3. Sub occipital Exploration for Presumed Cerebellar
tumor. No lesion exposed. Enormous cistern resembled
but be had seen in hydrocephalus due to serous
rachnoiditis.

3 o'clock. July 24. Attempted trans sinoidal Drainage
of Dilated Ventricles. - Bone flap replaced & success
as ~~drainage~~ haemorrhage was too great.

Marked improvement.

Case. Cerebellar cyst - typical

Philip Pauo. Surg No. 10,883.

29. 6 months headaches nause - occipital

Pain left side of head. Quadrunission frontal.

Head retracted. Hands pressed on forehead

Subjective Findings	Objective
Dizziness, tinnitus	Bilateral choked disc 2-3 d.
Headaches, mostly frontal	Suboccipital tenderness
Weakness L. side	Cervical rigidity
Diplopia, Vomiting.	Flexion of head on chest - great pain frontal
	Marked L. ataxia
	L. adiadocokinesis
	L. Hemi muscular hypotonicity
	Past pointing to L
	Tinnitus - L. ear
	Bradycardia
	Pos Romberg + reeling gait
	Nystagmus coarser to L.

Operation July 29. 1919

Suboccipital Exploration - Cyst of L. hemisphere

Nothing extra cerebellar found to explain the tinnitus

By needle only a few drops of straw colored fluid

obtained. No further evidence.

Case Cerebellar cyst. - typical

hilip Paus. Surg No 10,883.

d. 6 months headaches nause - occipital

Pain left side of head. Quadranission frontal.

Head retracted. Hands pressed on forehead.

Subjective Findings	Objective
Dizziness, Tinitus typical	Bilateral choked disc 2-3 d.
Headaches, mostly frontal	Subo ccipital tenderness
Weakness L. side	Cervical rigidity
Diplopia, Vomiting.	Flexion of head on chest - great pain frontal
	Marked L. ataxia
	L. adiadococinesia
	L. Hemi muscular hypotonicity.
	Past pointing to L.
	Tinnitus in L. ear
	Brady cardia
	Pos Romberg, reeling gait
	Nystagmus coarser to L.

Operation July 29. 1919

Sub occipital Exploration - Cyst of L. hemisphere

Nothing extra cerebellar found to explain the tinnitus

By needle only a few drops of straw colored fluid obtained. No further evidence.

Cases.

Gladys Mulry. 21 yrs. Cerebellar Cyst

years Frontal headache + vomiting attacks. 10 months failure of vision

and decompression. Vision not improved. Headache relieved some

Decompression not bulging.

Subjective	Objective	
Headache	R. subtemp. decompress.	Optic atrophy
Weakness	Bilateral exophthalmos	Erythematous exanthesis
Dizziness	No power convergence	Veins of eyelids dilated
Blind L. eye	Down + outward squint L. eye	Romberg +
Hallucinations of L.	~~Nasal Hemianopsia~~	Staggering gait - to R?
	Sl. L. facial paresis	Past pointing L. hand
	Choked disc 2-3 D	Adiadococinesis L.
	R. hemianopsia of R. eye & ear	

second test of eye grounds showed above observation incorrect ie that the vertical meridian in the R. field did not exist but there was a little vision to left of meridian ie usual type of declining field from pressure. nasal hemianopsia The first observation would have certainly made the lesion supratentorial. The visual hallucinations might also suggest occipital lesion.

Cerebellar operation (staggering gait, increased pressure, past pointing on left.)

Suboccipital region small. Bleeding profuse from bone + muscle hence a puncture of ventricle was done here. Bone thick instead of thin as usual. The puncture showed large dilated ventricle upholding suboccipital lesion. Large cyst c̄ yellowish fluid found in mid line over 4th ventricle. A cap of cyst removed and a circle of silver clips stopped bgr. (Fixation of lining c̄ Zenkers fluid?)



Turner

Case

Eliz. D'Arego - 41 - Cerebellar Cyst.

10 months ago influenza. - headaches at first frontal, now suboccipital. tired, sleepy, keeps her eyes closed. Some change in temperament. 5-6 weeks vomiting. 4-5 months hiccoughs

Subjective

Headaches (suboccipital at times + quite transient)
Vomiting, hiccoughing
Inability to stand or walk

Objective.

Romberg Pos. - Falls to R.
asynergia, reeling gait to R.
Muscle power diminished
Transient spontaneous nystagmus to R.
2 D. bilateral choked disc.
neck flexion painful.
Heel shin a little incoordinate L.

Operation

Bilateral incision. Because of protrusion a ventricular puncture was not made.
Large cyst in L. hemisphere 30 cc fluid. Walls fixed in Formalin. Cystic fluid Sp. gr. 1.004
Alb. ++
Sugar 0
Sediment - gelatinously.

Eyegrounds normal.

Case. Acoustic Neuroma. non case
Roupenian - 7.

P.2. ~~Sup.~~ 4 yrs. tinnitus L. ear, 3 yrs headache + occ. vomiting
2½ yrs. impairment of vision. ~~Hal~~ hallucinations of sight + color. – Head held to left.

Subjective.
Headache
Blindness
Inability to walk
Noises in L. ear.

Objective
Bilat. choke Disc 2D.
Pupils dilated. Nystag mus? more marked on looking to R.
Loss of L. corneal reflex, + facial overaction on L.
Rinné Neg. in L. ear. Weber lateralized to R.
Ataxia L. arm + leg.
Adiadicokinesia L.
Past pointing L. hand?
Suboccipital tenderness L. ~~hand side~~. ?
Romberg Neg.

Operation. Sub capsular Enucleation of Large Left Acoustic Neuroma surmounted by Large Dilated Lateral Cistern.
Bilateral suboccipital bone flap. To Left. a tumor size of pigeons egg was enucleated from lower pt. of post. fossa. Tumor size of pigeons egg.
Satisfactory convalescence.

Case. Chronic Nervous Dis.

Prophesies - 7.

Type writing. 3 yrs headache & nervousness
Impairs memory & vision. Melancholia & epilepsy.

Treated but to 8yr.

Headache
Dizziness
Inability to work
Been on it 5 yrs.

Started about Jan 20

Pupils slightly dilated. Reflexes normal on looking
at it.

Urine normal, pyelonephritis on it.
Urine Dig. on it 5 yr. Under Tetanology to 8
Urine & urine 8yr.
Tuberculosis?
Spitting of blood?
Recently blood?
Weakness 3 yr.

Diagnosis Insufficiency of large
Chronic Nervous Disorder complicated by
Tubercular & Renal Cretins.

Tubercular hereditary. To left a
Pain over of Pigeons eye was worse at from
Pt. of Post Fossa. Tumor over of Pigeons eye.

Prevent convulsions.

Case, Ciccola. Surg. No. 11,530
own.

+ nausea 1½ yrs previously. Headaches same time
parietal + occipital regions. 8 months ago sudden total
blindness c̄ occasional remissions. Vomiting frequent
c̄ nausea & dizziness. 1 month loss of sense of smell
Bilateral choke disc, dullness. - July 1st - R. subtemporal
decompression. Neg. findings.
Relief of head aches + improvement of anosmia
weeks later return c̄ findings below.

Subjective - Diff. in walking
Blindness
Pain in L. side body + weakness here.

Objective. 2nd ary optic atrophy
Anosmia ?
L. facial paresis
L. adiadicocinesia + astereognosis.
Hypesthesia to light touch, pain + temp c̄
complete loss of L. sided muscle sense.
Stimulat. of L. side body is disagreeable.
K.J. + Achilles exaggerated on L. c̄ ankle
clonus + neg. Babinski.
Nystagmus to R. conjugate deev. to L.

Op. Aug. 28. - 2nd Stage. Osteoplastic flap.
Disclosure of soft + vascular, reddish tumor
of upper R. frontal convolution.
Protrusion of dura here disclosed tumor. Pulse high
stopped.

Op. Sept 1. Bone defect enlarged across long. sinus
+ forward. Tumor extruding fast + blood under scalp.
Dura incised along the side of the sinus. Tumor enucleated
c̄ bare fingers covered c̄ dull sponges. T. single drain 8 days

Ciccola continued

Copied from Dr. Cushing

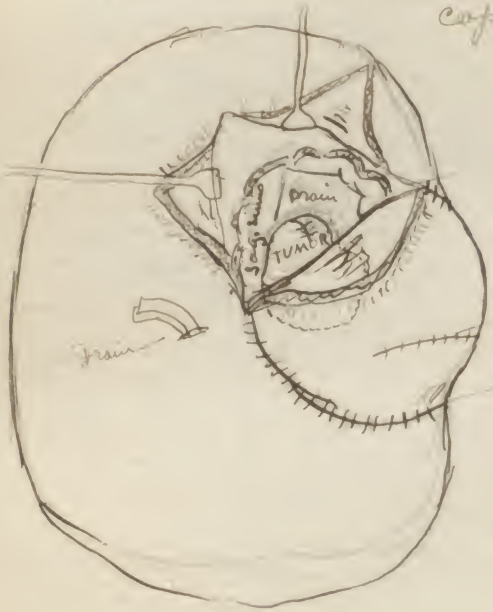

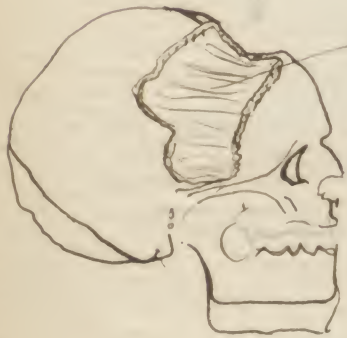

Operation continued.

Base of tumor pedicle broken off and vessels
ressed to either side c̄ fingers.

ad reaction to operation + attempted transfusion
rwa[illegible]cence of tendid.

Instruments.
S nose (straight.
Small cotton swabs
Periosteal elevator, j
Needle ?

Perp. cut must b
to Atlas as it
Bone Bleeding o top
Bone exposed down
and round bit
on either side o
hand brace + bit, b
longeurs of various
Large ~~bone~~ fixed bone a



~~Exposure not large~~
tapped via
Dura lifted by
director inserted + a
Spoon spatula under
Bleeder in dura stopped
lifted c spatula for in
and a blunt hook
Small amt. of liq

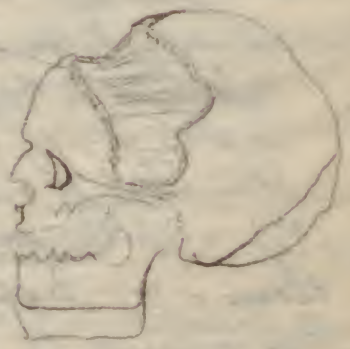

Ganglion. Cushing (Hunt High B.?)

Outline of incision — Top of ear to outer angle of brow — over face + angles — - Patient ~~on~~ head on side. high table

Incision defined. Temporal artery ~~cut~~ caught. Gauze had been spread over outline of incision. Avoid nerve at top. of incision from brow. Retractor holds temporal muscle down. Frontal sinus + ethmoid bone enlarged with rongeurs. Opening in bone sought 3 cm. in diameter + 2 cm to base. Spatula to hold down brain. The mid. meningeal is sought c̄ cotton sponges. Bleeding from base of skull stopped c̄ bone wax. Hemisphere ~~rep~~ reflected up + held c̄ spatula. much use of ~~cotton~~ sponges. Dura is loosed back a bit + a little ~~to~~ wax rest on base of skull. Ganglion exposed. dura cut c̄ a sting wire hook knife. Then dura reflected by wiping from ganglion until the 1st + 2nd div. + gang are exposed. The mid. meningeal art. crosses up + over the lateral side of gang. is over 1st branch.?)

The root of gang. is loosed c̄ a pair of sinuous forceps finished by a small flat hook. ——— 3 + IV

Sometimes the sensory root alone may be evulsed: root cut off in addition to avulsion + removed.

Head ~~also~~ raised for a time in order to lessen the flow of cerebrospinal fluid from nerve exits + lessen the blood flow. Small piece of muscle used as hemostatic over dural bleeding. Blood dropped before closure to fill c̄ cerebrosp. fluid + catch bleeders.



Rubber tissue placed on muscle edges to stop bleeding. Silks passed through muscle edges + op. ends held. Cavity filled c̄ saline + silks tied

Layer of silk at inner + outer layer of muscle
prot in c small French needle. Not tied tightly.
Line + interrupted silk in very edge of fascia. Cat gut would
rip this fascia (Cushing) The silk must be used.
fascia & all layer of the scalp close simultaneously
from one end to take drag off fascia. Tissues are not
tied but only napped + latter caught in silk ties
Skin closed c ~~strong~~ silk on straight needles.

Decompression. (Cushing)

Incision outlined by knife & scratch. Beginning just
~~above the~~ top of at 2 cm below top of ear + back of temp.
artery. - About 10 cm in length. Many
branches of temporal art. Hemostasis by
putting snaps on the aponeurosis at 1 cm.
intervals + allow weight of snaps to occlude.



Incision through fascia over temp. muscle through muscle,
and periosteum with periosteal elevators. Hole c bit
~~+ Dr~~ + electric power and enlargement c rongeurs
up to about 6 cm in diameter. The fascia + muscle is
reflected + lifted by decompression retractors
Incision in dura parallel to above incision
made by very cautious cuts c scalpel while
holding up the dura c forceps. Groove director inserted
& cut made on this. All bleeding pts in dura stopped
c silver clips. Three corneded flaps cut.
Hemisphere bulged out.

~~Cl~~ Closure (1) Interrupted silk on small French needle to
inner layer of temporal all tied at one a. (2) Same outer layer. (3) same

~~bat~~ in the fascia over muscle (only 3-4 sutures here.
(Periosteum ?) (4) Aponeurosis - same. May finish many
layers at one end to ~~coac~~ coax it together first. (5) Skin
straight needle silks. - Silver foil + ~~tang~~ gauze.
vaseline under ear + back of it + cotton under rim
of ear then roller bandage to head as a cap.

Most Instruments from Codman + Shurtleff. Boston

Bone Flap.

Preparation – Shave day of op. – Alcohol + Bichloride. One thickness bichloride gauze over whole head c hole torn for face. Incision previously outlined. Bichloride towel about crown and thick rubber tourniquet. Gauze cut c scissors over incision. Gray sheet c hole tied to head c strings.
Incision through scalp, fingers of two assistants on edges wound for hemostasis. Snaps on galea g. 1 or 2 cm. Scalp reflected out + held c gauze sponges. Periosteum reflected (?). ~~Holes~~ 4 holes made in circle of incision c perforator + burr (Hudson) + now sawed. Giggley saw carriers (sometimes 2 to prevent saw injuring dura) + saw pulled through. Shelving cuts made. Periosteal elevators on each side pry up the flap which breaks across. Care splintering into brain. Sometimes necessary to cut off pieces of bone. Flap turned back. Exploration easy. Closure by careful approximation c silk.

Transsphenoid –

Pt. on back c head thrown back in Rose position. Mouth gag + ether tube apparatus (1) inserted. Throat sponged c sea sponges held by second nurse at special table. Face cleaned a little c bichloride. Bichloride towels to face till mouth + nose only showed. Adrenalin sponges in nares early. Upper lip + teeth cleaned. Upper lip retracted. Frenum incised in line of lip attachment. End of septum removed. Mucous membrane elevated from septum by various small periosteal elevators. Septum removed c Ballinger knife (2) and ~~long~~ duck bill rongeurs (3) mucous membrane
also Rt. angled chisel (4)

tracted c̄ deep retractors[5] and muc. m cleared deeper down.
Most of septum removed. Bivalve speculum[6] metal dilators used inside these? inserted. Sponging from time
time c̄ adrenalin and with hydrogen peroxide. Sphenoid bed
removed till base of cella is exposed. This is a bitten
above rongeurs and with the punch[7] Dura
long dural knife hook[8] - never saw tumor removed. He uses
seal spoon. To close. Dichloramine sponge placed ~~in bases~~.
, while 3 cat gut stitches are placed in premuc incision
sponge removed on string + stitches tied. Large gauze
& rubber tissue drains covered c̄ vaselene inserted in
either nares so Pend just does not press on back of
site.















Wilms.
Dilators Sizes # 15
17
19
21

Knife - Boil 1 min.
Scissors etc " 3 min.
Instruments " 10 min.

Solutions used
Klotz-Jones Sol.
Zenker
Formalin 10 %.

Bone Flap.

Preparation - Shave day of op. Alcohol + Bichloride. Bin
thickness bichloride gauze over whole head c hole torn for
Incision previously outlined. Bichloride towel.
and thick rubber tourniquet. Gauze cut c
incision. Gray sheet c hole tied to head c strings
Incision through scalp, fingers of two assistants on s
for hemostasis. Snaps on galea q. 1 or 2 cm. Scalp reflec
+ held c̄ gauze sponges. Periosteum reflected(1). ~~Hole~~ 4 or 5
made in circle of incision c̄ perforator + burr (Hudson) + round
Giggley saw carriers (sometimes 2 to prevent saw injuring
dura) + saw pulled through. Shelving cuts
made. Periosteal elevators on each side pry up
which breaks across. Care splintering cuts bra
times necessary to cut off pieces of bone. Flap tu
Exploration easy. Closure by careful approxima
silk.

Transsphenoid —

Pt. on back c̄ head thrown back in Rose position. Mouth gag +
ether tube apparatus(1) inserted. Foot sponged c̄ sea sponges held by se
nurse at special table. Face cleaned a little c̄ bichloride. Bichloride towels
to face till mouth + nose only showed. Adrenalin sponges in nares early
upper lip + teeth cleaned. Upper lip retracted. Frenum incised in line
lip attachment. End of septum removed. Mucous membrane elevat
from septum by various small periosteal elevators. Septum remo
c̄ Ballinger knife(2) and ~~long~~ duck bill rongeurs.(3) Mucous membran
also Rt. angled chisel(4)

retracted c̄ deep retractors[5] and muc. m cleared deeper down. metal dilators used mid line (?)
+ bost of septum removed. Bivalve Speculum[6] inserted. Sponging from time to time c̄ adrenalin and with hydrogen peroxide. Sphenoid keel and cells removed till base of skull is exposed. This is gone bitten away c̄ the bone rongeurs and with the punch[7] Dura incised c̄ long dural knife hook[8] – never saw tumor removed. He uses hypophyseal spoon. To close. Dichloramine sponge placed ~~in nares~~ cavity while 3 cat gut stitches are placed in premuc incision + sponge removed on string + stitches tied. Large gauze filled rubber tissue drains covered c̄ vaseline inserted in either nares so end just does not press on back of palate.

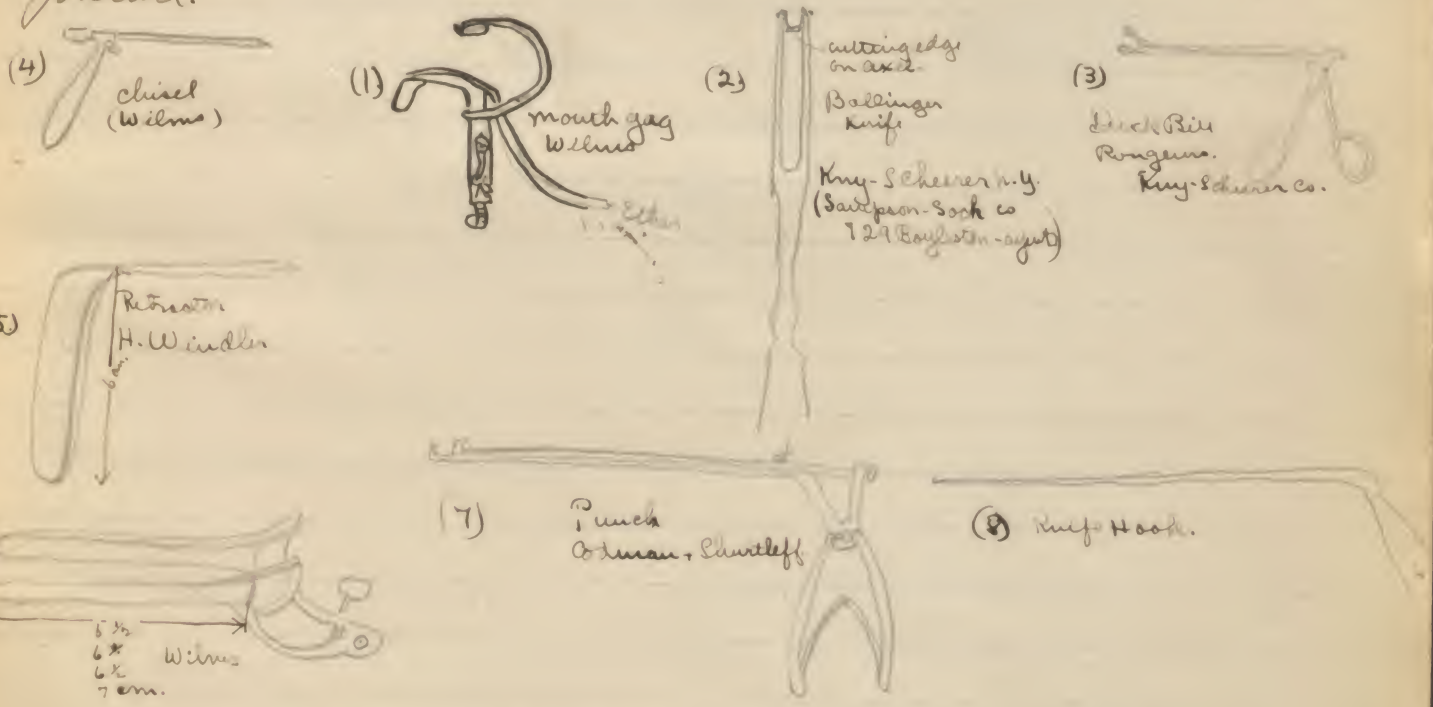



Knife – Boil 1 min.
Scissors etc " 3 min.
Instruments " 10 min.

Solutions used
Klotz-Jones Sol.
Zenker
Formalin 10 %.

Transfrontal approach to Pituitary region.

Incision just above the brow. Perforator + Burr holes + bone flap made c̄ Gigglay saw. Bone flap reflected.

topped if easily reached. Cerebral hemisphere reflected up. Roof of orbit R. or L. hemisphere chiselled smooth but not perforated. Pituitary region reached and dura cut c̄ dural hook. Dissection c̄ sponges. Tumor removed c̄ spoon. Hole filled c̄ salt + usual closure in layers after replacing bone flap.

[illegible]

[illegible] Pyrogallic acid

KOH. NaOH. 2.15 [illegible] Pyrogallic acid. [illegible]

[illegible] keep away from air. [illegible]

(see Nicolaus – Methods of Air analysis for [illegible])

[illegible] Oliver – Leeb Gorman Co 1136 Monadnock Bldg.

Calif. Portable apparatus. Burette should be [illegible]

by them.

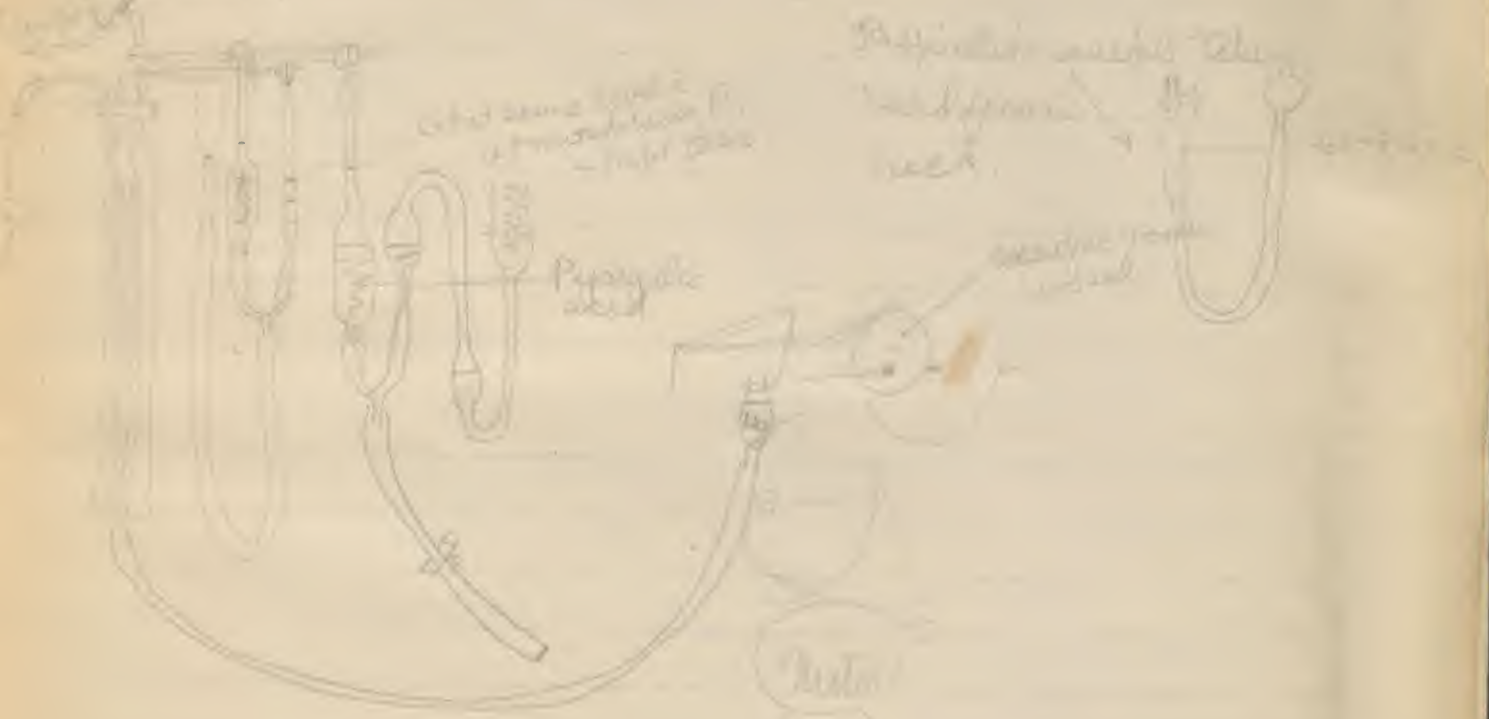

Burette [illegible]

[illegible]

Perimetry

Fine red. – Discs 1/4 (1/2 cm diam)

1/10 (.25 diam)

.6 m.

.015

.12

Also 4 1/2 cm Diam.

2 cm. Diam.

Perimeter Black tin.

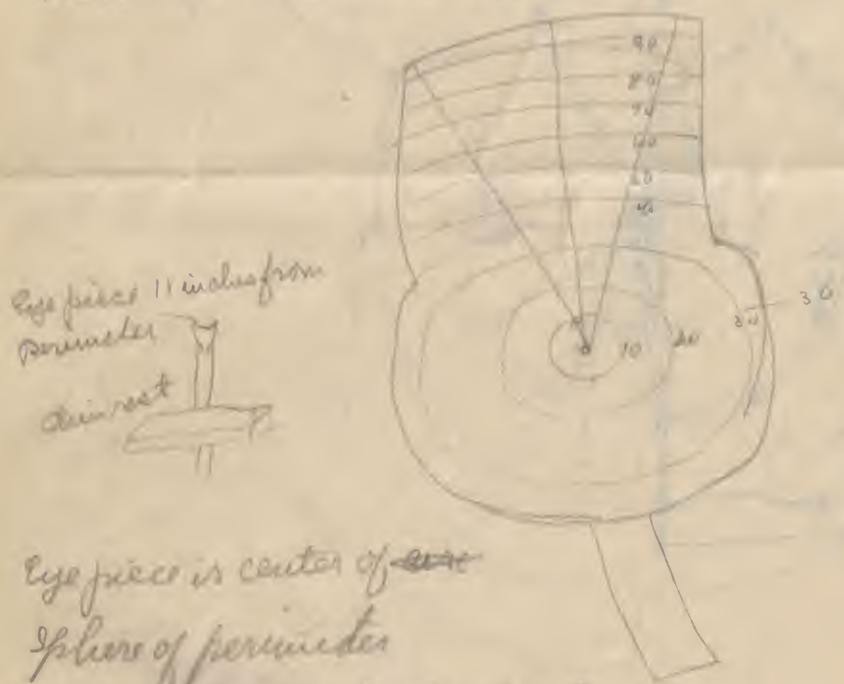

Eye piece is center of ~~arc~~ Sphere of perimeter

Perimeter turned stopping to a click every 30°

Horse shoe of light immediately behind chair of patient. Large black back ground behind perimeter.

obert Rosenbloom

Date Sept 19



Perfield.

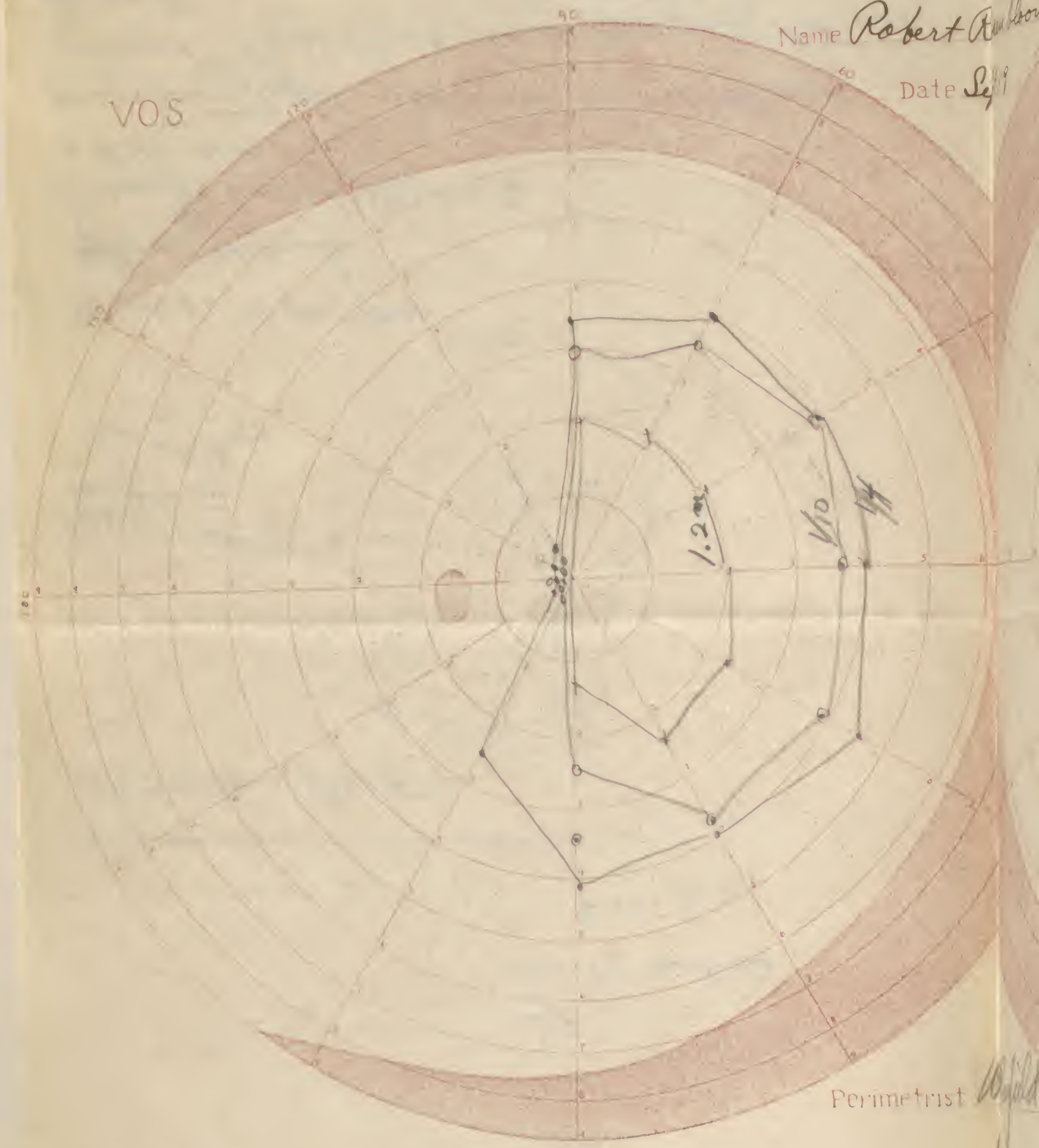
VOS
Name Robert Ambro
Date Sept
90
60
30
180
1.2
1/10
1/4
Perimetrist